

EVALUATION OF RECONSTRUCTION OF ZYGOMATIC FRACTURE WITH CUSTOMIZED TITANIUM IMPLANTS USING COMPUTER ASSISTED TECHNIQUES (A CLINICAL TRIAL)

Nada M. Ghabbour ¹**BDS*, Magued H. Fahmy ²*PHD*, Noha Y. Dessoky ³*PHD*

ABSTRACT

BACKGROUND: Zygomatic defects that follow trauma may lead to severe esthetic and functional deformities such as ipsilateral facial widening in addition to facial flattening. There are many ways to treat the damage by using either ready-made or custom-made appliances and implants. Accurate zygomatic anatomic reconstruction is the key to reestablishing favorable facial normality.

AIM OF THE STUDY: To clinically evaluate the application of customized titanium implants in reconstruction of zygomatic fractures to restore normal pre-traumatic status (facial contour, diplopia, occlusion, and abnormal infraorbital nerve sensation).

PATIENTS AND METHODS: Twelve patients who had recent zygomatic bone fractures were included in the current study. Patients were treated with customized titanium implants. Ocular motility, diplopia, infraorbital nerve affection, occlusion, and facial symmetry were assessed preoperatively, and then after 24 hours, one week, four weeks, and six weeks. Additionally, a radiographic examination was done immediately to assess the accuracy of bone reduction.

RESULTS: None of the included patients displayed post-traumatic diplopia, and thus, diplopia was not observed in any of them postoperatively. At the second follow-up, six patients (50%) reported a subjective aberrant sensation along the compromised infraorbital nerve. By the end of the follow-up period, all patients had restored their normal sensation, despite the presence of post-traumatic abnormal sensation. Nevertheless, all patients suffered from pre-operative malocclusion which was immediately corrected after the surgery. Normal facial contour was also immediately restored after the surgery in all enrolled patients.

CONCLUSION: In the treatment of zygomatic bone fractures, customized titanium implants demonstrated promising clinical outcomes, making them an excellent reconstructive option with exceptional compatibility, surgical precision, and predictability.

KEYWORDS: Zygomatic complex reconstruction, customized plates, computer-aided techniques.

RUNNING TITLE: Evaluation of customized titanium implants in zygomatic-fracture reconstruction.

1 Dentist in Ministry of Health and Population

2 Professor of Oral and Maxillofacial Surgery, Faculty of Dentistry, Alexandria University.

3 Lecturer of Oral and Maxillofacial surgery, Faculty of Dentistry, Alexandria University.

* Corresponding Author:

E-mail: nada.ghabbour93@gmail.com

INTRODUCTION

The skeletal unit consists of the zygomatic bone and maxilla which are together referred to as the zygomaticomaxillary complex (ZMC). Because of their anatomical and functional interdependence, these two bones are described as a complex as they articulate with one another over a larger area and are typically affected by the same traumatic events. By including the orbital floor, infra-orbital rim, and lateral wall, this dual complex also makes up a significant portion of the orbit. Occipital-zygomatic-maxillary complex is another name for the ZMC (1).

ZMC fractures are frequently referred to as "tripod, tetrapod, or pentapod" fractures due to their

numerous articulations. Due to the prominent anatomical position of the zygoma and its proximity to essential nearby structures like the globe, ZMC fractures frequently result in severe cosmetic and functional impairments. These fractures are challenging to precisely reduce and fix because of their complicated anatomical structure, numerous articulations, and multi-planar deformation (2).

The most frequent problems associated with ZMC fractures include aberrant ocular motility, asymmetric globe level, diplopia, circumorbital ecchymosis, abnormal sensation over the infraorbital nerve ramifications, and occlusal discrepancies. All these signs demand immediate surgical interventions (3).

The facial transverse width and antero-posterior projection are provided by the zygoma, which spans

the face like a powerful jutting bar. Its role in establishing facial esthetics and ocular function is what provides its significant clinical value (2).

Whether autogenous, allogenic, or alloplastic, the literature clearly contrasted the different materials used to repair zygomatic fractures and evaluated the advantages and disadvantages of each material (4). A wide range of alloplastic materials are readily available in the market, and a significant number of studies assessing the advantages and disadvantages of various materials had been conducted. (5). Recent trends in computer-assisted surgery and virtual planning have made it possible to use a variety of novel materials to create customized implants. (5).

Titanium implants are the most commonly used non-resorbable hardware in reconstructing orbito-zygomaticomaxillary complex fractures. They are widely used to repair a plethora of defects of varying sizes because of their malleability which enables their recontouring into various forms while maintaining their rigidity and stability. This is in addition to restoring the bony structural outline and function (5).

Due to their low density and specific elastic modulus, these metals exhibit mechanical properties that are similar to that of the bone. Titanium is one of the few materials that can naturally fulfil the requirements of implantation in the human body. It is lightweight, robust, and completely biocompatible (6).

Implantation is a potential assault on the chemical, physiological, and mechanical integrity of the human body. The most challenging application of implants in the human body is that the materials used must be "fit and forget" when implanted since they cannot be easily maintained or replaced. Thus, the effectiveness and dependability of implants and other medical and surgical tools are crucial to saving lives and providing long-term pain and suffering alleviation (7).

In the field of maxillofacial trauma, only a few studies evaluated the effectiveness of zygomatic reconstruction using customized titanium implants. This necessitates evidence-based development of titanium implants to be used in reconstructive surgery for zygomatic fractures (2).

AIM OF THE STUDY

To clinically evaluate the application of customized titanium implants in reconstruction of zygomatic fractures to restore normal pre-traumatic status (facial contour, diplopia, occlusion, and abnormal infraorbital nerve sensation).

MATERIALS AND METHOD

Twelve patients with zygomatic fractures who needed surgical intervention participated in this prospective study between April 2022 and June 2023. Patients were recruited from the Outpatient Clinic of the Alexandria University Teaching

Hospital and underwent surgery in the Department of Oral and Maxillofacial Surgery, Faculty of Dentistry, Alexandria University.

The study protocol was approved by the Research Ethics Committee, Faculty of Dentistry, Alexandria University. Individuals who participated in this study signed full informed consents. Zygomatic fractures of the involved patients were unilateral, accompanied with other facial fractures, and necessitated open reduction with internal fixation. Adult patients of both genders who agreed to complete the follow-up examinations for at least three months after the surgery were included in this study. Patients with a resultant diplopia were also included in the study. Patients with globe rupture, previous zygomatic fractures, and medically compromised patients were excluded from the current study.

Sample size estimation

The minimal sample size is calculated based on a previous study aiming to evaluate the application and clinical outcomes of this technique. Based on Zhang et al.'s, (2) results, adopting a power of 80% (b error=0.20) to detect a standardized effect size (d)=0.854 in the primary outcome (deviation of the zygomatic eminence), and α error =0.05, the minimum required sample size was found to be 10 patients. The anticipated dropout rate is 20%, so, the sample size will be increased to **12 patients** to control for any withdrawals. The sample size was calculated using G*Power version 3.1.9.2.

Materials

Titanium discs (MAGNUM HYPRONE) were used in the current study. Disk Dimensions: 14.75 mm diameter with 0.8 mm thick. Two mini screws with lengths ranging from 5 -7 mm, and plates, were used when needed (JEIL Medical Corporation Company: Seoul, Korea).

Preoperative evaluation

The cause, date, location, and nature of the traumatic incident were all obtained, as well as the personal information. Patients' previous dental and medical histories were recorded, along with a complete assessment of their general condition. Additionally, swelling, flattened cheeks, circumorbital ecchymosis, and subconjunctival bleeding were evaluated. This thorough examination aimed to spot any visual anomalies, including diplopia, ocular motility, abnormal eye level, and occlusion inconsistencies.

Distribution of the infraorbital nerve's sensation was subjectively evaluated. All patients underwent preoperative occipitomental radiography and performed a CT scan to check for any zygomatic fractures (Figure 1).

Preoperative virtual planning

A virtual model created from a CT scan mirrored the healthy side onto the fractured side as a guidance for the fractured bone reduction. The virtual model was used to precisely reduce the fractured segments to their pre-traumatic ideal

positions. After bones had been virtually reduced, customized implants _with a thickness of 0.5-1.0 mm_ were designed in the virtual model (Figure2). To print the plates, each design was loaded in a Standard Template Library (STL) format to an appropriate software that runs on a printing machine. W.Philadelphia Street, USA (MC X5: Dentsply Sirona Susquehanna Commerce). Preoperative virtual planning was conducted to assist in achieving a similar clinical scenario and, consequently, the best intraoperative outcomes.

Operative procedure

All patients underwent surgery under general anesthesia with nasotracheal intubation. The surgical field was disinfected with a povidone-iodine surgical scrub solution before the patient was draped in sterile cloths with only the surgical site left exposed. The fracture lines were exposed to allow access to the segmented bones. Tissues dissection was performed to provide a wide and clean surgical site to expose all the fracture lines simultaneously. The fractured bone segments were then reduced and brought in continuity into appropriate anatomical positions, either bimanually _if possible _ or using instruments such as; zygomatic bone hook, periosteal elevator, and Bristow elevator according to the fracture site, degree and direction of segment rotation.

To ensure that all of the entrapped tissue had been released, a forced duction test was performed afterwards. During the surgery, customized titanium implants were placed into their planned positions. The implants were then secured to the bone around the fracture line by 5-7 mm mini-screws. The flap tissues covering the implants' external surface were securely sutured (Figure 3).

All patients were instructed to use an extra-oral ice pack for 12 hours starting immediately after the surgery. Antibiotic, anti-inflammatory, and analgesic medications were provided also prescribed. The listed clinical parameters were evaluated after 24 hours, one week, four weeks, and six weeks by a complete follow-up. A 10-point Visual Analogue Scale (VAS) was employed to assess postoperative pain (0–1 = None, 2–4 = Mild, 5–7 = Moderate, and 8–10 = Severe). Symptoms of infection of the stitched wounds, such as swelling, redness, heat, pus discharge, and tenderness were evaluated. The infra orbital nerve's sensory capabilities were subjectively assessed by asking the patient if their sensation in the cheek-midface area had changed.

Objective assessment: Through the pinprick test (nociceptive method), precise locations comprised the midway of the lower eyelid, center of the lateral half of the nose, middle of the upper lip, and middle of the zygoma. According to whether or not the palpebral fissure was occluded, postoperative edema was diagnosed. The "follow my finger" test was used to evaluate diplopia and ocular movements. Postoperative ocular ecchymosis had been documented.

Radiographic evaluation: An immediate postoperative CT scan was carried out to examine the precision of reduction and fixation.

Statistical Analysis:

Data were collected and entered to the computer using Statistical Package for Social Science (SPSS) program for statistical analysis (Version 25.0) (8). Data were entered as numerical or categorical, as appropriate. Kolmogorov-Smirnov test of normality revealed significance in the distribution of most of the variables, so the non-parametric analysis was adopted (9). Data were described using minimum, maximum, mean, median, standard deviation, standard error of the mean, 95% CI of the mean and 25th to 75th percentile (10). Kendall's *W* (also known as Kendall's coefficient of concordance), a non-parametric statistic, was used (11). Kendall's *W* ranges from 0 (no agreement) to 1 (complete agreement). Statistical significance was tested at *p* value <.05 (12).

RESULTS

Cases epidemiology, and societal statistics of the 12 included patients were described. The mean (SD) age was 39.42 (14.39) years, with a male to female ratio of 4:1. Road Traffic Accidents (RTA) were the most prevalent etiological cause of fractures in this study. In the present study, all patients (100.00%) had Zygomatic Maxillary Complex fractures, 66.67% had infra-orbital rim fracture, 66.67% had zygomaticofrontal suture fracture, 66.67% had infra-orbital rim fracture, 50.00% had mandibular fracture, 25.00% had zygomatic arch fracture, 16.67% had supra-orbital rim fracture and 16.67% had orbital floor fracture. (Table 1)

Table 1: Summarizes the study's demographic information from clinical evaluation within the follow-up period.

Sex		
-	Male	9 (75.00%)
-	Female	3 (25.00%)
Age		
-	Min-Max	22.00-64.00
-	Mean ± SD	39.42±14.39
-	SEM	4.16
-	95% CI for mean	30.27-48.56
-	25 th Percentile – 75 th percentile	27.00-51.00
Side		
-	Right	7 (58.33%)
-	Left	5 (41.67%)
Associated Fractures ^a (n=12)		
-	Zygomatic Maxillary Complex	12 (100.00%)
-	Infra-orbital rim fracture	8 (66.67%)
-	Zygomaticofrontal suture fracture	8 (66.67%)
-	Infra-orbital rim fracture	6 (50.00%)
-	Infra-orbital rim fracture	3 (25.00%)
-	Mandibular Fracture	2 (16.67%)
-	Zygomatic Arch	2 (16.67%)
-	Supra-orbital rim fracture	
-	Orbital floor fracture	
Restoring normal bone contour		
-	24 hours PO	12 (100.00%)
-	Three months PO	12 (100.00%)
Infraorbital nerve affection		
-	24 hours PO	12 (100.00%)
-	1 week PO	6 (50.00%)
-	4 weeks PO	0 (0.00%)
-	6 weeks PO	0 (0.00%)

n: number of patients, PO: Postoperative

SD: Standard deviation, SEM: Standard error of the mean, CI: Confidence Interval

^a : any patient can have more than one type of associated fracture(s)

Within the follow-up period, the reported postoperative pain (VAS) of all patients were statistically significant (Kendall's W = 1.00, Test statistic = 12.00, $p=.001$).

At the first follow-up visit, all patients described an aberrant sensation along the afflicted infraorbital nerve, which was objectively verified by pin prick nociceptive test at each of the designated sites. By the end of the follow up; all of the included patients had returned to normal sensation, despite the presence of post-traumatic abnormal sensation. None of the included patients displayed post-traumatic diplopia, and thus, diplopia was not observed in any of them postoperatively.

After the first follow-up period, ecchymosis and edema were observed in all patients; a significant recovery was noticed by the sixth postoperative week ($p=.001$ and $p=.001$, respectively), depending on whether orbital fissure occlusion was present or not. The radiographic investigation using an immediate postoperative CT demonstrated accurate bone reduction (Figure 4).

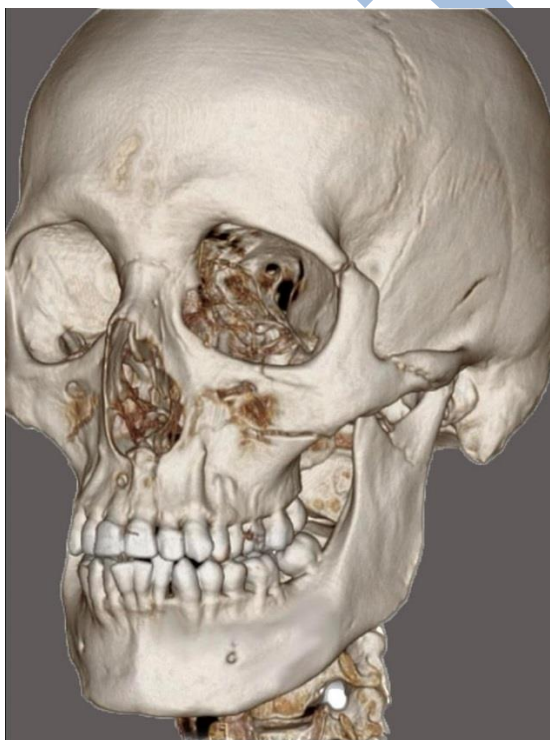

Figure (1): Radiographic picture of preoperative 3D Computed-Tomography Scan.

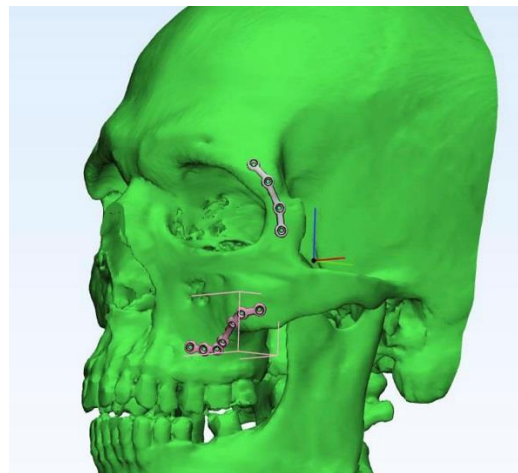


Figure (2): Photographic picture demonstrating preoperative Virtual planning of the titanium implants.

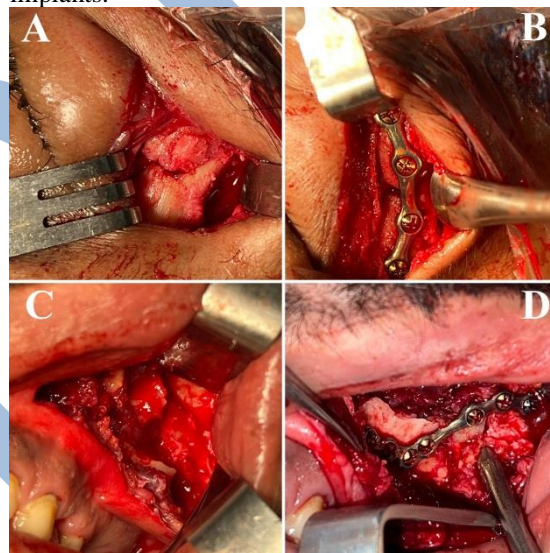


Figure (3): Photograph showing: (A, C), fractured segments. (B, D) fractures reduction and fixations via customized titanium plates.

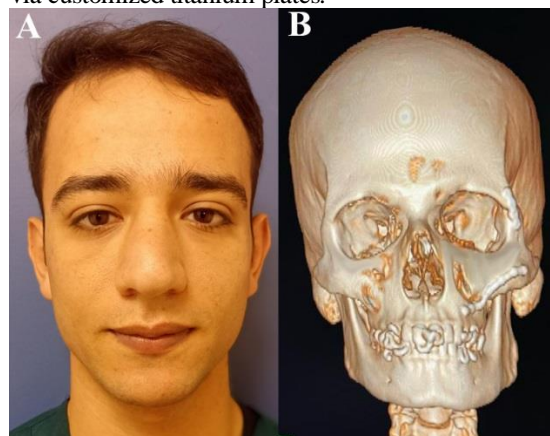


Figure (4): Photograph demonstrate: A, 6 weeks postoperative clinical picture. B, Immediate postoperative 3D Computed-Tomography Scan.

DISCUSSION

Owing to the lack of prospective studies, as well as the technological improvement and fast prototyping technology, this study was designed to evaluate the clinical outcomes and performance of customized titanium implants in primary reconstruction cases (2). Since the zygoma occupies a prominent anatomical position which is adjacent to other important structures like eyes, zygomatic fractures frequently have significant cosmetic and functional consequences. Precise reduction and stabilization of these fractures is difficult due to their complicated anatomical structure, multiple articulations, and multiplanar deformations (2).

Titanium implants are the most often chosen material in craniomaxillofacial reconstruction during the recent years. This specific implant seemed to be helpful for reshaping the zygomatic region's anatomical features and enhancing aesthetic results. However, because of its poor flexibility, this customized implant is hardly modifiable and cannot be adjusted during surgeries (13).

Titanium has several uses in the medical field owing to its biocompatibility and high mechanical qualities. Since titanium can be machined into the precise geometrical configuration with minimum thickness without losing its properties, it is a desirable material for construction of customized implants (6). This study was performed in order to better evaluate the clinical and radiographic success of customized titanium implants in zygomatic fractures repair.

Analysis of the epidemiological data of the study participants revealed a male to female ratio of 4:1 with mean (SD) age of 39.42 (14.39). Evaluation of the demographic characteristics of zygomaticomaxillary complex fractures by Ellis et al. (2004), are comparable to these findings (14). In all the included cases, facial fracture sites were reported to be concurrent. According to Blumer et al. (2018), 40% of the ZMC fracture cases evaluated also had another fractures (15).

In this study, customized titanium plates with a thickness range of 0.5-1.0 mm were chosen, similar to Wang et al. (2020) (16). Stock titanium implants have a thickness of 1.0-1.5 mm and serve as the most popular alloplastic material for ZMC repair. Customized implants do not require surgical modifications as they precisely fit the zygomatic bone's anatomical structure. Titanium's rigidity necessitates a minimum thickness to prevent its deformation (2).

This study showed that customized titanium implants had extremely good clinical results in treating zygomatic fractures. The mid-face stability following surgery is not taken into consideration when using a standard mini-plate, which could lead to plate deformation or screw loosening, giving the mid-face an asymmetrical appearance, as mentioned by Wang et al. (2020). Understanding the stress/strain

biomechanical dynamics of the facial skeleton during zygomatic fractures' repair and healing is necessary for designing fixation implants. There is still no consensus on the best method for developing an internal fixation implant for zygomatic fractures (2, 17).

According to the literature and biomechanical principles, the fixation implant should be constructed as a thin plate that is not excessively rigid in order to have a stress-shielding effect. It also cannot be too soft to cause instability during repairs, and must reestablish the mechanical function of the undamaged bone (17-19). However, before surgery, customized 3D printed implants need to be carefully designed according to the patient's condition (16).

In the initial follow-up period, transient paresthesia along the infraorbital nerve's ramification route was noted. However, by the end of the follow-up period, all patients recovered their normal sensation. Whenever an orbito-zygomatic fracture arises, the infraorbital nerve becomes subjected to damage or compressed within a crashed infraorbital canal. Ozer et al. (2016) provided additional clarification, noting that in order to achieve infraorbital nerve healing, an accurate reduction is crucial (20), which accomplished this study's primary goal.

The degree of palpebral fissure occlusion was used to determine the severity of postoperative periorbital edema. In the initial 24-hour follow-up, all the included patients showed significant edema which extended with five of them during first week. By the end of the recommended follow-up time (6 weeks), all had fully recovered. According to Dickinson and Gausas (2006), postoperative edema manifests as occlusion of the palpebral fissure because the principal superficial and deep lymphatic draining ports aggregate at the canthus lymphatic vessels for lymphatic drainage of the periorbital tissues (21).

Ecchymosis was found in all patients after 24 hours post-operatively which significantly improved by the end of the follow up period. Susarla and Peacock (2014); reported that patients with zygomatic fractures frequently have pain, ecchymosis, and edema over the lateral orbit, upper and lower eyelids, loss of malar projection, and blunting of the lateral canthus when compared to the unaffected side (3, 22).

In the current study, none of the included patients experienced post-operative diplopia at any point during the follow up period. This disagrees with Zimmerer et al. (2016) who reported diplopia in 24.6% of the patients, and Chepurnyi et al. who observed diplopia in 29.4% of the patients (23). Treatment of patients with diplopia depends on the proper release of the restricted tissues together with the accurate reduction of zygomaticofrontal suture and inferior orbital rim.

Normal occlusion was restored in all the involved patients along the entire follow up periods, and this

finding agreed with the results of Tripathi et al. (24), and Zhang et al.(2017-2019) (2).

As a reconstructive alternative, customized titanium implants have some drawbacks including its prolonged preoperative processing period making it more difficult to be applied in the reconstruction of primary zygomatic fractures. Several trauma centers advise immediate management of traumas, particularly those with orbital abnormalities. This may account for the long-standing success of customized titanium hardware in managing the large reconstruction of missing facial bones following massive resection in oncology cases (2). Moreover, compared to the stock titanium hardware, adoption of a printed fabricated titanium implant imposes a greater cost burden on the patient.

CONCLUSION

In light of the limitations of this study and the favorable clinical and radiographic results, it can be concluded that using customized titanium implants to treat zygomatic fractures is a promising reconstructive option with excellent compatibility, surgical accuracy and foreseeability. With a focus on restoring the symmetrical facial skeleton, customized titanium implants outperformed the frequently used ready-made titanium implants in terms of clinical performance. However, using customized titanium implants need longer preoperative fabrication time and higher cost.

CONFLICT OF INTEREST

The authors declare that they have no conflicts of interest.

FUNDING STATEMENT

The authors received no specific funding for this work.

REFERENCES

1. Maturo S, Lopez MA. Zygomatico-orbitomaxillary complex fractures. *Oper Tech Otolaryngol.* 2008;19:86-9.
2. Zhang WB, Yu Y, Mao C, Wang Y, Guo CB, Yu GY, et al. Outcomes of Zygomatic Complex Reconstruction With Patient-Specific Titanium Mesh Using Computer-Assisted Techniques. *J Oral Maxillofac Surg.* 2019;77:1915-27.
3. Susarla SM, Peacock ZS. Zygomaticomaxillary complex fracture. *Eplasty.* 2014;14:ic27.
4. Shetty P, Senthil Kumar G, Baliga M, Uppal N. Options in orbital floor reconstruction in blowout fractures: a review of ten cases. *J Maxillofac Oral Surg.* 2009;8:137-40.
5. Patel N, Kim B, Zaid W. Use of Virtual Surgical Planning for Simultaneous Maxillofacial Osteotomies and Custom Polyetheretherketone Implant in Secondary Orbito-Frontal Reconstruction: Importance of Restoring Orbital Volume. *J Craniofac Surg.* 2017;28:387-90.
6. de Viteri VS, Fuentes E. Titanium and titanium alloys as biomaterials. *Tribology-fundamentals and advancements.* 2013;1:154-81.
7. Titanium Alloys in Medical Applications. 2013. Available at: <https://www.azom.com/article.aspx?ArticleID=1794>.
8. SPSS I. IBM Corp. Released, Statistics for Windows, Version 25.0. Armonk, NY: IBM Corp. 2017.
9. Field A. *Discovering Statistics Using IBM SPSS Statistics.* 4th ed. London, California, New Delhi: SAGE Publications Ltd; 2013.
10. Greenland S, Senn SJ, Rothman KJ, Carlin JB, Poole C, Goodman SN, et al. Statistical tests, P values, confidence intervals, and power: a guide to misinterpretations. *Eur J Epidemiol.* 2016;31:337-50.
11. Kendall MG, Smith BB. The problem of m rankings. *Ann Math Stat.* 1939;10:275-87.
12. Curran-Everett D. Evolution in statistics: P values, statistical significance, kayaks, and walking trees. American Physiological Society Bethesda, MD; 2020. p. 221-4.
13. Rotaru H, Schumacher R, Kim SG, Dinu C. Selective laser melted titanium implants: a new technique for the reconstruction of extensive zygomatic complex defects. *Maxillofac Plast Reconstr Surg.* 2015;37:1.
14. Ellis E, 3rd, Reddy L. Status of the internal orbit after reduction of zygomaticomaxillary complex fractures. *J Oral Maxillofac Surg.* 2004;62:275-83.
15. Blumer M, Kumalic S, Gander T, Lanzer M, Rostetter C, Rücker M, et al. Retrospective analysis of 471 surgically treated zygomaticomaxillary complex fractures. *J Craniomaxillofac Surg.* 2018;46:269-73.
16. Wang YT, Chen CH, Wang PF, Chen CT, Lin CL. Design of a Metal 3D Printing Patient-Specific Repairing Thin Implant for Zygomaticomaxillary Complex Bone Fracture Based on Buttress Theory Using Finite Element Analysis. *Appl Sci.* 2020;10:4738.
17. Prado FB, Freire AR, Cláudia Rossi A, Ledogar JA, Smith AL, Dechow PC, et al. Review of In Vivo Bone Strain Studies and Finite Element Models of the Zygomatic Complex in Humans and Nonhuman Primates: Implications for Clinical Research and Practice. *Anat Rec (Hoboken).* 2016;299:1753-78.
18. Janovic A, Saveljic I, Vukicevic A, Nikolic D, Rakocevic Z, Jovicic G, et al. Occlusal load distribution through the cortical and trabecular bone of the human mid-facial skeleton in natural dentition: a three-dimensional finite element study. *Ann Anat.* 2015;197:16-23.
19. Pakdel AR, Whyne CM, Fialkov JA. Structural biomechanics of the craniomaxillofacial skeleton under maximal masticatory loading: Inferences and critical analysis based on a

validated computational model. *J Plast Reconstr Aesthet Surg.* 2017;70:842-50.

20. Ozer MA, Govsa F, Kazak Z, Erdogmus S, Celik S. Redesign and treatment planning orbital floor reconstruction using computer analysis anatomical landmarks. *Eur Arch Otorhinolaryngol.* 2016;273:2185-91.
21. Dickinson AJ, Gausas RE. Orbital lymphatics: do they exist? *Eye (Lond).* 2006;20:1145-8.
22. Ellstrom CL, Evans GRD. Evidence-based medicine: zygoma fractures. *Plast Reconstr Surg.* 2013;132:1649-57.
23. Chepurnyi Y, Chernogorskyi D, Kopchak A, Petrenko O. Clinical efficacy of peek patient-specific implants in orbital reconstruction. *J Oral Biol Craniofac Res.* 2020;10:49-53.
24. Tripathi N, Goyal M, Mishra B, Dhasmana S. Zygomatic complex fracture: A comparative evaluation of stability using titanium and bio-resorbable plates as one point fixation. *Natl J Maxillofac Surg.* 2013;4:181-7.

ADJ