

# EVALUATION OF THREE DIMENSIONAL PRINTING AND PREOPERATIVE ADAPTATION OF MINIPLATES IN TREATMENT OF MANDIBULAR FRACTURES (CLINICAL TRIAL)

Hesham M. Abdou AbdElfattah<sup>1\*</sup> BDS, Ossama Sweedan<sup>2</sup> PhD,  
Noha Y. Dessoky<sup>2</sup> PhD

## ABSTRACT

**BACKGROUND:** The craniomaxillofacial trauma field is in continuous evolution and modernizations owing to the implementation of computer-aided design and manufacturing (CAD-CAM), creation of a preoperative anatomically reduced three-dimensional (3D) bone model has the potential to drastically reduce operating room time and operating room costs.

**Aim:** Was to evaluate the clinical performance and the state of postoperative occlusion of a pre-adapted miniplates using 3D printed for the treatment of mandibular fractures.

**MATERIALS AND METHODS:** 10 patients had recent mandibular fracture was treated using pre-adapted miniplates on 3D model. Fixation time was assessed intraoperatively. Clinical follow up was conducted after 24-hours, one, four, six, twelve and twenty-four weeks. In addition, a radiographic investigation was performed after twelve weeks to estimate the mean bone density across the fracture line.

**RESULTS:** The study male to female ratio was 2.33:1 with mean age of  $27.40 \pm 5.38$  years. The mean reported intraoperative fixation time was  $9.43 \pm 4.25$  min. all patients reported a highly statistically significant improvement in the assessed clinical parameters. Across the radiographic follow up period, all of the patients reported a highly statistically significant increase in the mean bone density values ( $p < 0.001^*$ ).

**CONCLUSION:** the use of preoperatively adapted fixation plates in mandibular fracture management was associated with optimal occlusal and anatomical patient rehabilitation with decline in operating time while at the same time minimal increase in the processing time.

**KEYWORDS:** 3D printed model, miniplate, Mandible, Fracture.

**RUNNING TITLE:** Preoperative Adaptation of Miniplates in Treatment of Mandibular Fractures.

1 B.D.S Faculty of Dentistry Alexandria University

2 Professor of Oral and Maxillofacial Surgery Department, Faculty of Dentistry, Alexandria University, Alexandria, Egypt

3 Lecturer of Oral and Maxillofacial Surgery Department, Faculty of Dentistry, Alexandria University, Alexandria, Egypt

\* Corresponding Author:

**E-mail:** [hmosaad8@gmail.com](mailto:hmosaad8@gmail.com)

## INTRODUCTION

The majority of trauma treated by oral maxillofacial surgeons are mandibular fractures, they are considered as the first or second most prevalent bone fractures (1). The prominence and the position of the mandible and that it is the only mobile bone in the face increases the incidence of mandibular fractures (2). Road traffic accidents, sport injuries, interpersonal violence and falling from heights are the most common etiologies of mandibular fractures (3).

The mechanism of injury and the direction of the vector of the force determine the location and the pattern of the fractures, in addition the characteristics of the resulting injury depends on the patient's age, presence of the teeth and the physical properties of the causing agent (4).

Mandibular fractures have many classifications, Dingman and Natvig classified them anatomically into: midline, symphyseal, parasymphiseal, body,

angle, ramus, condylar process, coronoid process and alveolar process fracture (5).

Treatment of mandibular fractures by re-approximation of fractured fragment and immobilization of the fractured mandible by using circum-dental wiring and external bandages, since then many methods have been introduced including wires, metal splints, external fixation and titanium plate osteosynthesis (6).

Chamby and his colleagues developed and modified miniplates which are small plates with a screw diameter of 2.0 mm. Treating mandibular fractures with these plates is very effective due to their stability and durability. The pearl of being less palpable so there is no need to subsequent plate removal. The ideal osteosynthesis line on the mandible was defined by Chamby according to biomechanical study and the distribution of masticatory stresses along the mandibular anatomical regions. According to this study the ideal line of osteosynthesis are as follows:

behind the mental foramina the plate is inserted below the roots but above the inferior alveolar canal, at the angle of the jaw the plate is inserted on the inner broad surface of the external oblique line, and in the anterior region between the mental foramina due to the torsion strains at this region two plates should be applied to neutralize it (7).

The craniomaxillofacial trauma field is in continuous evolution and modernizations owing to the implementation of computer-aided design and manufacturing (CAD-CAM).(8-18)

Stereolithographic creation of a preoperative anatomically reduced three-dimensional (3D) bone model, utilizing a Computed Tomography (CT) CAD software, has the potential to drastically reduce operating room time and operation room costs (8, 10-13). A predictable reconstructive solution can be obtained from the preoperative adaptation of the fixation hardware with an associated decrease in operative time and cost (18, 19).

The purpose of this study was to evaluate the clinical performance and the state of postoperative occlusion of a pre-adapted miniplates using 3D printed mandibles for the treatment of mandibular fractures. We hypothesized that the use of 3D printers to create models and preoperatively bend mandibular reconstruction plates resulted in a proper occlusal relation and anatomical alignment.

## MATERIALS AND METHODS

### Study design

This study was a prospective clinical and radiographic study. Participants were recruited from the Outpatient Clinic of Alexandria University Teaching Hospital and operated in the Oral and Maxillofacial Surgery Department, Faculty of Dentistry, Alexandria University. Sample size calculation was conducted on a sample consisting of ten patients who meet the inclusion criteria.

### Inclusion criteria

The criteria for including patients are as follows: Adult patients older than 18 years old suffering from recent, uninfected and minimally displaced or unfavorable mandibular fractures which demand open reduction and internal fixation. The patients medically fit for general anaesthesia with no gender predilection that agreed to present for follow-up visits for a minimum postoperative period of 3 months.

### Exclusion criteria

Exclusion criteria were medically compromised patients, patients suffering from pathological fracture, old fracture and comminuted fracture and patients with infection.

### Preoperative assessment

Full personal data was obtained in detail along with details about the trauma, including cause, time, date, place and type of assault. Intraoral and extraoral physical examination was performed to note any swelling, facial deformity, jaw deviation during

function, bleeding, step deformity, alteration in bone contour, and soft tissue laceration was inspected and recorded.

### Radiographic examination (19)

A routine orthopantomogram (OPG) had been taken for each patient, followed by CT-scan to examine the number and pattern of fracture lines, degree of displacement and tooth presence in fracture line. The CT-Scan had been used in the creation of the preoperative 3D-model (Figure 1).

### Three-dimensional model Designing

Planning was accomplished using specialized CT, DICOM (Digital Imaging and Communication in medicine) format, segmentation software (Materialise innovation suite NV, Belgium) with surface-based rendering for surgical planning and simulation. Customized Stereolithographic model had been designed and fabricated in the following steps:

2D section images had been used to eliminate all of the soft tissue, only highlighting bone and dental tissues, using the segmentation software (MIMICS; Materialise NV, Belgium), a 3D reconstruction of the segmented mandible along with dental hard tissue had been created, the fracture segments had been virtually repositioned and reduced anatomically using the simulation module (repositioning option) in the designing software (3Matic; Materialise NV, Belgium), verification done in the axial and coronal planes and condylar position was checked in relation to the glenoid fossa, the image had been transferred to a specialized software (NETFAB, Autodesk, CA) on a machine (Sony SCS 8100, Sony, Taiwan). so that the anatomically reduced mandibular model had been printed and the mini plates bended and adapted preoperatively (Figure 2).

### Surgical procedure

Patients had undergone all the necessary laboratory investigations to obtain clearance for operation from the anesthesia specialist. All patients had been treated under general anaesthesia using nasotracheal intubation.

The surgical field had been scrubbed with povidone-iodine surgical scrub solution, fracture line had been exposed and mobilized Followed by bone reduction into proper anatomical occlusion, inter maxillary fixation (IMF) had been temporarily secured to provide proper occlusion that served as a guide for fracture reduction. The pre-operatively adapted miniplate had been applied following the well-established Champy's recommendations, Closure of the surgical wound had been done (Figure 3).

### Operative Data

To validate the importance of the preoperative adaptation, the time period from the start to the end of the fracture fixation processes was measured.

### Early postoperative care

All patients had been instructed to apply ice pack extra-orally starting immediately postoperatively

for 12 hours. A antibiotic prescription was performed for 5 days postoperatively. Instruction of soft, fluid, high protein, high calorie diet had been given for all patients for 4 weeks postoperatively.

#### **Clinical follow-up phase**

A thorough follow-up had been performed after 24-hours, one week, four weeks and six weeks for the assessment of postoperative pain, Occlusal status, signs/symptoms of infection, paresthesia along the length of the mandibular alveolar-mental nerve, and soft tissue dehiscence.

#### **Radiographic evaluation (20)**

Preoperative CT scan had been obtained, immediate CT-scan had been used to assess the adequacy of fracture line reduction and fixation, and then another CT had been taken at 12<sup>th</sup> week to estimate the mean bone density at the fracture line in comparison with the immediate postoperative scan. Digital orthopantomogram (OPG) had been taken after one month and after 6 weeks to evaluate fracture healing progression.

#### **Statistical analysis**

Normality was checked using descriptive statistics, plots (histogram and box plot) and Shapiro Wilk test. Age, Bone density and Pain scores readings were presented using mean and standard deviation. All qualitative variables were presented using count and percentage.

Age, Bone density at each time point and percent change in bone density were compared between groups using independent t test. Pain scores at each time point were compared using Mann Whitney u test. All qualitative variables were compared using Chi Square test.

Differences between each time point within groups were compared using One Way Repeated measures ANOVA regarding the bone density while Friedman test was applied to compare the pain scores. Significance level was set at 0.05. Data was analyzed using IBM SPSS statistical software (version 25).

## **RESULTS**

### **Cases Epidemiology and Demographic Data**

Regarding the demographic data of this study, the gender analysis reported seven males in opposing to 3 female patients with male to female ratio of 2.33:1. The mean reported age in this study was  $27.40 \pm 5.38$  years, that ranged from 18 years to 39 years. The study consisted of 10 patients of which 8 cases are presented with anterior mandible fracture, while only 2 patients are presented with posterior mandible fracture. Out of the examined cases in this study, five cases suffered from symphyseal fracture, three cases suffered from parasymphiseal fractures, and only two cases are presented with angle fracture.

Fracture etiological analysis in this study revealed road traffic accidents as the prevailing etiological factor for the suffered maxillofacial traumatic event (n= 4), this was followed by interpersonal violence and claimed falls by 3 cases each.

In 60% of the included patients, other associated maxillofacial fractures were presented while none of the cases reported non-maxillofacial region traumatic events. Associated parasymphiseal fracture were reported in three cases, while bilateral sub-condylar were reported in 2 cases. Only one case reported associated Lefort one fracture.

#### **Operative Data**

The intraoperative miniplate fixation duration reported in the study ranged from 6 min to 19 min, with a mean period of  $9.43 \pm 4.25$  min (Table 1).

#### **Clinical Evaluation Data**

A thorough preoperative, 24-hour, one-week, four-weeks, and six-weeks follow-up was performed. Regarding the postoperative pain analysis, VAS was utilized as the calliper to assess the subjective pain of the patients. Across the follow-up period, a highly statistically significant reduction in the mean value of the reported postoperative pain analysis was reported ( $p < 0.001^*$ ). Analysis of the postoperative occlusion was inspected at each postoperative period. All of the operated patients reported a satisfactory intercusp and canine relationship in the postoperative clinical follow-up period. Regarding the mouth opening analysis, an interincisal calliper was utilized to measure the postoperative mouth opening at each follow up period. The mean value of the reported postoperative maximum mouth opening analysis was reported ( $p < 0.001^*$ ) to have increased over the follow-up period, and this increase was highly statistically significant (Figure 4).

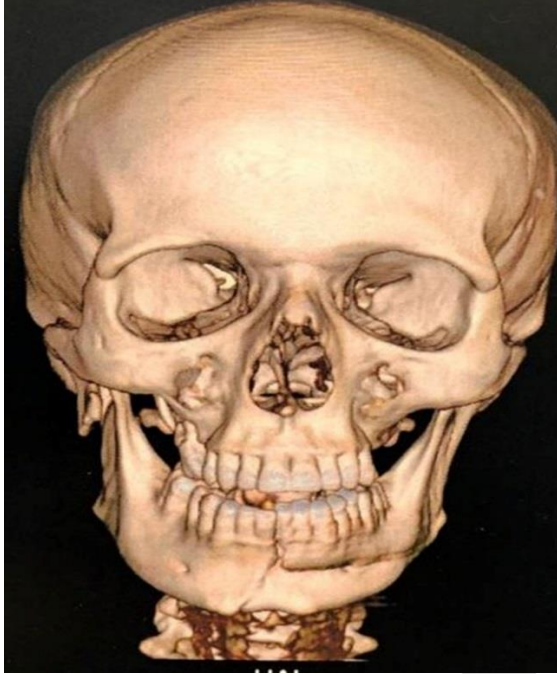
Analysis of the postoperative occlusion was inspected at each postoperative period. All of the operated patients reported a satisfactory intercusp and canine relationship in the postoperative clinical follow-up period. Subjective analysis of the postoperative sensory nerve function was performed at each postoperative period for the patients with anterior mandibular fracture (n=8). In the first follow up period, 3 patient reported disturbance in the mental nerve function, which remained disturbed up till the third follow up period where only one patient reported improvement in the sensation. By the end of the clinical follow up period, all affected patients reported regain in the sensory nerve function. The statistical analysis reported an insignificant difference across the follow up period.

Regarding the postoperative wound healing, only one patient reported intraoral wound dehiscence in the first postoperative period. In the first postoperative week, other two patients were presented with dehiscence to add up to a total of 3 patients. All of the affected patients were managed with wound debridement and mouth wash for three weeks. In the third follow up period, all three of the affected patients reported healing in the intraoral wound.

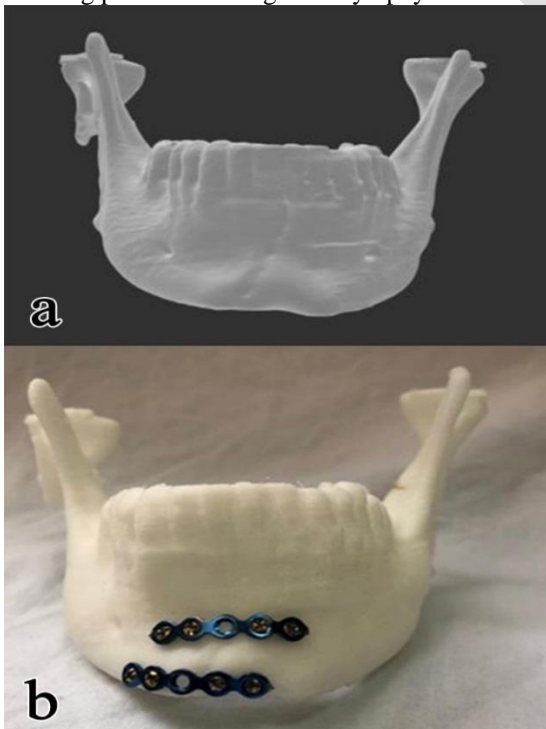
#### **Radiographic Evaluation Data**

Radiographic analysis of the accuracy of the reduction was performed by the utilization of an immediate postoperative CT, which revealed proper anatomical reduction in all of the examined cases. A bone density analysis to monitor the healing pattern across the fractured site was performed by the acquisition of a three months postoperative CT

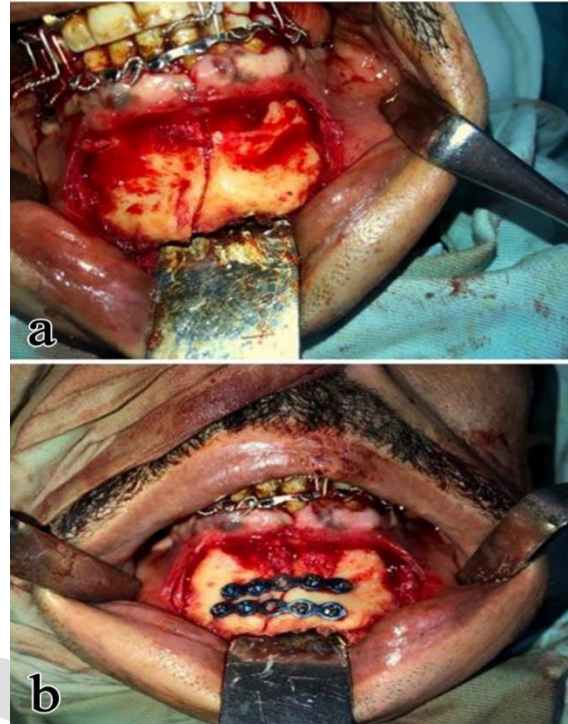
scan and comparing the bone density values with the immediate postoperative and the preoperative computed tomography records. Across the radiographic follow up period, all of the patients reported a highly statistically significant increase in the mean bone density values ( $p < 0.001^*$ ) (Table 2) (Figure 5) (Figure 6).



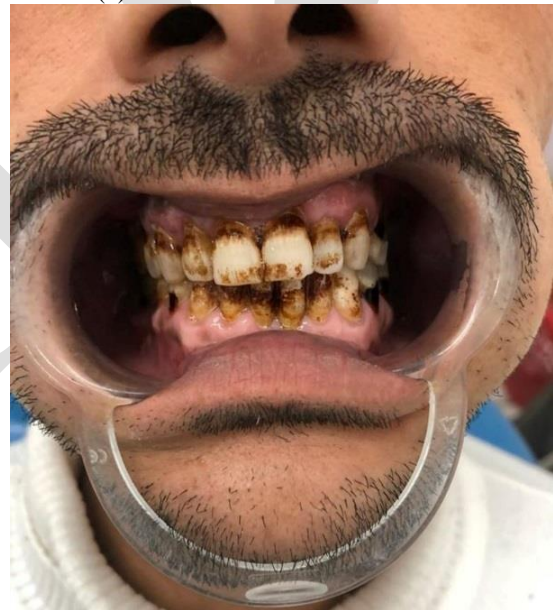**Figure (1):** Preoperative radiographic examination showing patient suffering from symphyseal fracture.



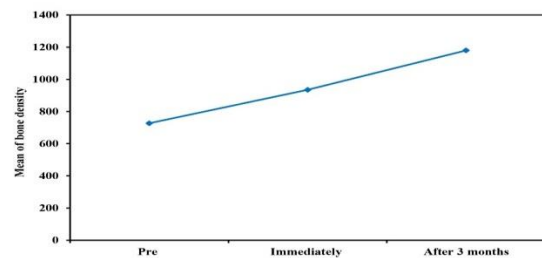
**Figure (2):** 3D-Printed bone model with sufficient anatomical and functional reduction (a). Preoperative adaptation of the miniplates (b).



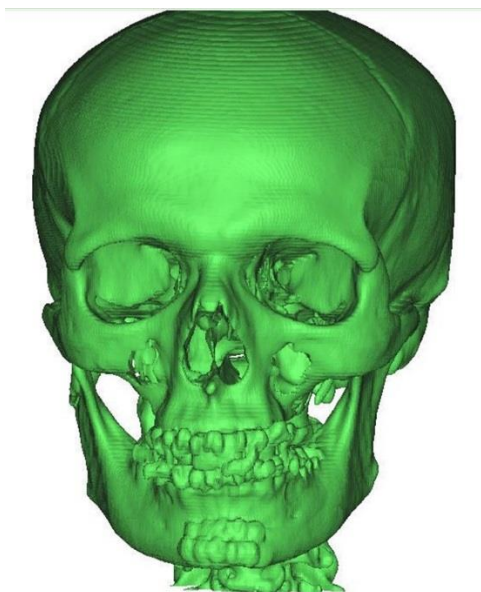**Figure (3):** Operative picture of the exposed fracture line (a). Operative picture of the miniplate fixation (b).



**Figure (4):** Postoperative picture of satisfactory occlusal state at the end of the follow-up period.



**Figure (5):** Comparison between the different periods according to bone density.



**Figure (6):** Post operative CT scan.

**Table (1):** Descriptive analysis of the studied cases according to duration (n =8).

|          | Min. – Max. | Mean ± SD.  | Median |
|----------|-------------|-------------|--------|
| Duration | 6.0 – 19.0  | 9.43 ± 4.25 | 8      |

SD: Standard deviation

**Table (2):** Comparison between the different periods according to bone density

| Bone density | Pre                   | Immediately           | After 3 months     | F       | P1     |
|--------------|-----------------------|-----------------------|--------------------|---------|--------|
| Min. – Max.  | 620.0 – 809.0         | 875.0 – 994.0         | 1082.0 – 1307.0    | 107.756 | <0.001 |
| Mean ± SD.   | 727.0 ± 75.0          | 935.0 ± 45.0          | 1180.0 ± 78.0      |         |        |
| Median (IQR) | 758.0 (632.2 – 784.9) | 942.0 (882.9 – 979.3) | 1177 (1088 – 1249) |         |        |
| P2           |                       | <0.001*               |                    |         |        |
| P3           |                       |                       | <0.001*            |         |        |

F: F test (ANOVA) with repeated measures, Sig. bet. periods were done using Post Hoc Test (Bonferroni)  
 P1: p value for comparing between the studied periods.  
 P2: p value for comparing between preoperative and Immediate postoperative scans.  
 P3: p value for comparing between 3 months postoperative and preoperative scans.  
 \*: Statistically significant at p ≤ 0.05  
 IQR: Inter quartile range  
 SD: Standard deviation

**DISCUSSION**

The utilization of the contemporary and innovative radiographic techniques and computer-assisted expertise provided the oral and maxillofacial filed with a plethora of gains regarding the clinical performance of the common procedures (21). The aim of this study was to implement the use of reverse engineering and 3D-printing technologies in the

management of patients suffering from mandibular fractures with preoperatively adapted miniplates.

The study demographic analysis showed a 2.33:1 male to female ratio with a mean reported age of 27.40 ± 5.38 years. This study reported a lower male to female ratio than that reported by Melek and Sharara (2016), 4.5:1, and Mabrouk et al (2014), 5.7:1 (22, 23).

A similar age group was reported in El-Mahallawy and Al-Mahalawy (2018) regarding management of anterior mandible fracture with a mean reported age of 29 ± 1.87 years (24). In a study regarding the epidemiology of maxillofacial fractures in Egypt, Mabrouk et al (2014), conducted that patients in the third decade of their life a more likely to be affected by facial trauma (23). The demographic analysis falls in line with the common knowledge that male individuals in their third decade of life are more engaged in the day-to-day activities in the society and are exposed to outdoor daily life risks in eastern communities.

The study consisted of 10 patients of which 8 cases are presented with anterior mandible fracture, while only 2 patients are presented with posterior mandible fracture. Fracture etiological analysis showed a slight prevalence for road traffic accidents over interpersonal violence and claimed falls. In the indexed literature, there is a conformity regarding the main aetiology of maxillofacial fractures. Most of the reported demonstrates that Road Traffic Accidents (RTA), assaults, falls, and sports-related injuries are the most prevalent etiological factors especially in developing countries (25-27). This is due to careless driving, bad road conditions caused by lack of maintenance, and ineffective enforcement of traffic safety laws.

Analysis of the postoperative occlusion was inspected at each postoperative period. All of the operated patients reported a satisfactory inter-cuspal and canine relationship in the postoperative clinical follow-up period. None of the enrolled patients required selective extraction, grinding, or elastics. Dessoky et al (2020) reported similar outcome where a virtual planning was performed for the management of mandibular fracture (28). In this study the use of the preoperative virtual planning along with the use of temporary intra-operative inter-maxillary fixation ensured that the reduction was based on not only anatomic relation, but also functional occlusal relation.

Regarding the clinical performance in this study, the postoperative pain reported a highly statistically significant reduction in the mean reported VAS score across the follow-up period (p<0.001\*), while the mouth opening analysis reported a highly statistically significant increase in the mean value (p<0.001\*). Regarding the postoperative wound healing, a total of 3 patients reported intraoral wound dehiscence in the first postoperative week. All of the affected patients were managed with

wound debridement and mouth wash for three weeks, and in the third follow up period, all three of the affected patients reported healing in the intraoral wound. El-Mahallawy and Al-Mahalawy (2018) reported One patient (14.3%) with intraoral wound dehiscence at the first postoperative week (24). All of the reported patients were those suffering from anterior mandibular fracture with dissection of the mentalis muscle in order to access the fracture line.

For the 8 patients with anterior mandibular fracture, subjective assessment of the postoperative sensory nerve function was performed. By the end of the clinical follow up period, all affected patients reported regain in the sensory nerve function. The statistical analysis reported an insignificant difference across the follow up period. El-Mahallawy et al (2018) reported 33.3% of the cases with nerve disturbance in the first follow-up period (29). Early disturbance is a normal encounter for the common practice of mental nerve skeletonization for adequate access of the fracture line, along with the extensive retraction intraoperatively. The preoperative planning and the minimal manipulation may be aided in the less retraction intraoperatively and the easier placement of the fixation device.

To validate the importance of the preoperative adaptation, the time period from the start to the end of the fracture fixation processes was measured. The duration reported in the study ranged from 6 min to 19 min, with a mean period of  $9.43 \pm 4.25$  min. King et al (2018) evaluated the effect of the utilization of a preoperatively adapted fixation in the reduction of operative time in the management of mandibular fracture. They reported a mean operative time of  $6.9 \pm 0.3$  min in the preoperatively adapted group in comparison to  $22.8 \pm 2.1$  min in the conventional group (30).

The majority of the cases in this study were of anterior mandible fracture ( $n=8$ ). King et al (2018) performed a statistical correlation between their descriptive variables and primary outcome variable, time for plate application (30). They reported a mean time of 17.7 min in fractures of anterior part of the mandible. King et al (2018) reported value falls in line with that reported in this study (30). Preoperative surgical planning employing computer aided design and manufacturing has started to pay off for oral and maxillofacial surgery. Current studies on orthognathic surgery and free flap and graft have demonstrated time-cost benefits (31-34). A well-documented drawback to the utilization of virtual planning in the maxillofacial trauma management is the increased preoperative processing time and delay in the management of the patients (30, 35). In this study, a coinvent protocol was performed in order to limit the processing time waste. A consistent protocol of emergency department patient evaluation and acquisition of CT-

scan, image preparation and virtual reduction, model virtual creation, 3D-printing of the model using Fused Deposition Modelling (FDM) technology, preoperative plate preparation, and finally sterilization of the customized plate was utilized in all of the enrolled patients within one working day. This is an extensive improvement over the usual time required by bioengineering model printing companies of 1 to 2 weeks (30, 35). Furthermore, King et al (2018) demonstrates that the use of in-house printing further decreases the processing time to a maar 3 hours, however it increases the start-up coast as the availability of in-house printers is scares (30). The slight increase in processing time reported in this study demonstrates that the utilized virtual workflow is a timely-effective treatment modality with a vast resultant decrease in the more important operative time.

Radiographic appraisal of the accuracy of the reduction was performed by the utilization of an immediate postoperative CT, which revealed proper anatomical reduction in all of the examined cases. Furthermore, monitor the healing pattern across the fractured site was scrutinised by bone density analysis in a three-month postoperative CT scan and comparing the bone density values with the immediate postoperative and the preoperative computed tomography records. The results of bone density analysis are coherent with the indexed knowledge of bone healing patterns, as across the radiographic follow-up period all of the patients reported a highly statistically significant increase in the mean bone density values ( $p<0.001^*$ ). Doblal et al (2004) examined the increase in bone density in patients with mandibular fracture managed with miniplates and they reported a similar significant improvement in the recorded bone density (26).

The mean reported preoperative bone density values was  $727.0 \pm 75.0$  HU, which increased to a mean value of  $935.0 \pm 45.0$  HU in the immediate postoperative scan and to  $1180.0 \pm 78.0$  HU in the three-month record. El-Mahallawy and Al-Mahalawy analysed the bone density improvement with different fixation schemes in anterior mandibular fracture (24). They reported similar values in the group managed with miniplates.

The study opted the use of radiographic appraisal to demonstrate the optimal anatomical performance of the preoperative virtual trauma reduction procedure. This is proven by the proper anatomical reduction in all of the examined cases, which revealed the accuracy of the preoperatively fabricated model in giving the surgeon an insight of the proper anatomical shape of the fracture-affected mandible. Furthermore, the adequate radiographic performance was affected by the choice of the fixation scheme. In this study all of the cases were managed following the Swiss Association for the Study of Internal Fixation (AO/ASIF) guidelines with adherence to the Champy's functionally stabilized fixation scheme in

order to attain a stable fixation with a brisk functional recovery (36). The existence of absolute fracture fixation with minimal inter-fragmentary mobility is an imperative precondition in order to have a predictable bone healing as this led to rapid return to function with the avoidance of wound infection.

The modern trauma centres deemed the use of the conventional radiographic techniques as an inconvenient practice, owing to their's variation in exposure, the limited 2D fracture line perspective, and the positional restrictions in trauma patients.(24, 29) Schulze et al (2004) concluded that the use of a single conventional projection for the actual detection of a fracture line is erroneous (27). The use of computer tomographic scans is considered as a gold standard practice in trauma centres as it provides multi-planner 2D images with minimal radiation exposure, in the novelist of scanners, which provides the surgeon with an initial view of the fracture site and degree of displacement. While the use of Cone-Beam scans provides a lower radiation exposure, its availability in trauma centres is still not that popular (37). Furthermore, the use of multidetector CT scan provided a more accurate analysis of the bone density in Hounsfield unit and better resolution for the virtual planning procedure (38, 39). The utilization of virtual preoperative planning mandates the acquisition of a preoperative CT-scan for accurate representation of the mandible with its fractured segments (37).

The contemporary innovations in bioengineering and reverse engineering have left a massive impact on the maxillofacial field, and the facial trauma field is no exception (37, 40,). The preoperative virtual fracture reduction and the utilization of the 3D-printing technology to transfer this virtual relation intraoperatively have gravely impacted the accuracy of the reduction procedure with great reduction in the precious operation time.(30, 35) Despite increase in cost due to increased preoperative facilities required, the significant reduction in the operation time overshadows any excess expenses as surgical room operation remains one of the costliest features in facial trauma care. Furthermore, the preoperative visualization of the reduction anatomical form helps in improving the learning curve for unaccustomed residents and young surgeons (30, 35).

With respect to the limitation of this study, the optimal clinical and radiographic outcome reported in this study illustrates that the use of preoperatively adapted fixation plates in mandibular fracture management is associated with optimal occlusal and anatomical patient rehabilitation with decline in operating time while at the same time minimal increase in the processing time.

#### CONFLICT OF INTEREST

The authors declare that they have no conflict of interest.

#### FUNDING STATEMENT

The authors received no specific funding for this work.

#### REFERENCES

1. de Matos FP, Arnez MF, Sverzut CE, Trivellato AE. A retrospective study of mandibular fracture in a 40-month period. *Int J Oral Maxillofac Surg.* 2010;39:10-5.
2. Salam A. Pattern and management of mandibular fractures: a study conducted on 264 patients. *Pakistan Oral & Dental Journal.* 2007;27:20-5.
3. Natu SS, Pradhan H, Gupta H, Alam S, Gupta S, Pradhan R, et al. An epidemiological study on pattern and incidence of mandibular fractures. *Plast Surg Int.* 2012;2012:834364.
4. Fasola AO, Obiechina AE, Arotiba JT. Incidence and pattern of maxillofacial fractures in the elderly. *Int J Oral Maxillofac Surg.* 2003;32:206-8.
5. Dingman RO, Natvig P. *Surgery of facial fractures.* W.Saunders company; 1969. p142-144.
6. Fonseca RJ. *Oral and Maxillofacial surgery.* Saunders; 2017.p.146-172.
7. Haerle F, Champy M, Terry BC. *Atlas of Craniomaxillofacial Osteosynthesis. Anatomical Aspects and Biomechanical Considerations for the Body of the Mandible, the Midface, and the Cranium.* 2nd ed. New York: Germany Thieme Medical; 2009. p4.
8. Avraham T, Franco P, Brecht LE, Ceradini DJ, Saadeh PB, Hirsch DL, et al. Functional outcomes of virtually planned free fibula flap reconstruction of the mandible. *Plast Reconstr Surg.* 2014;134:628e-34e.
9. Cheng X, Yoo JJ, Hale RG, Davis MR, Kang H-W, Jin S. 3D printed biomaterials for maxillofacial tissue engineering and reconstruction—a review. *Open J Biomed Mater Res.* 2014;1:1-7.
10. Hanasono MM, Skoracki RJ. Computer-assisted design and rapid prototype modeling in microvascular mandible reconstruction. *Laryngoscope.* 2013;123:597-604.
11. Kim YC, Jeong WS, Park TK, Choi JW, Koh KS, Oh TS. The accuracy of patient specific implant prebent with 3D-printed rapid prototype model for orbital wall reconstruction. *J Craniomaxillofac Surg.* 2017;45:928-36.
12. Miloro M, Markiewicz MR. Virtual Surgical Planning for Inferior Alveolar Nerve Reconstruction. *J Oral Maxillofac Surg.* 2017;75:2442-8.
13. Seruya M, Fisher M, Rodriguez ED. Computer-assisted versus conventional free fibula flap technique for craniofacial reconstruction: an outcomes comparison. *Plast Reconstr Surg.* 2013;132:1219-28.
14. Wagner JD, Baack B, Brown GA, Kelly J. Rapid 3-dimensional prototyping for surgical repair of maxillofacial fractures: a technical note. *J Oral Maxillofac Surg.* 2004;62:898-901.
15. Winder J, Bibb R. Medical rapid prototyping technologies: state of the art and current

- limitations for application in oral and maxillofacial surgery. *J Oral Maxillofac Surg.* 2005;63:1006-15.
16. Boeckx P, Essig H, Kokemuller H, Tavassol F, Gellrich NC, Swennen GR. Presentation and Evaluation of a Modified Wax-Bite Dental Splint for Surgical Navigation in Craniomaxillofacial Surgery. *J Oral Maxillofac Surg.* 2015;73:2189-95.
  17. Bui TG, Bell RB, Dierks EJ. Technological advances in the treatment of facial trauma. *Atlas Oral Maxillofac Surg Clin North Am.* 2012;20:81-94.
  18. Cui J, Chen L, Guan X, Ye L, Wang H, Liu L. Surgical planning, three-dimensional model surgery and preshaped implants in treatment of bilateral craniomaxillofacial post-traumatic deformities. *J Oral Maxillofac Surg.* 2014;72:1138.e1-14.
  19. Broyles JM, Wallner C, Borsuk DE, Dorafshar AH. The role of computer-assisted design and modeling in an edentulous mandibular malunion reconstruction. *J Craniofac Surg.* 2013;24:1835-8.
  20. Johnson C. Measuring Pain. Visual Analog Scale Versus Numeric Pain Scale: What is the Difference? *J Chiropr Med.* 2005;4:43-4.
  21. El-Mahallawy Y, Abdelrahman HH, Al-Mahalawy H. Accuracy of virtual surgical planning in mandibular reconstruction: application of a standard and reliable postoperative evaluation methodology. *BMC Oral Health.* 2023;23:119.
  22. Melek LN, Sharara AA. Retrospective study of maxillofacial trauma in Alexandria University: Analysis of 177 cases. *Tanta Dent J.* 2016;13:28.
  23. Mabrouk A, Helal H, Mohamed AR, Mahmoud N. Incidence, etiology, and patterns of maxillofacial fractures in ain-shams university, cairo, egypt: a 4-year retrospective study. *Craniofacial Trauma Reconstr.* 2014;7:224-32.
  24. El-Mahallawy Y, Al-Mahalawy H. Herbert Cannulated Bone Screw Osteosynthesis in Anterior Mandibular Fracture Treatment: A Comparative Study With Lag Screw and Miniplate. *J Oral Maxillofac Surg.* 2018;76:1281.e1-e8.
  25. Saman M, Kadakia S, Ducic Y. Postoperative maxillomandibular fixation after open reduction of mandible fractures. *JAMA Facial Plast Surg.* 2014;16:410-3.
  26. Doblare M, Garcia J, Gómez M. Modelling bone tissue fracture and healing: a review. *Open Eng Frac Mech.* 2004;71:1809-40.
  27. Schulze D, Heiland M, Thurmann H, Adam G. Radiation exposure during midfacial imaging using 4- and 16-slice computed tomography, cone beam computed tomography systems and conventional radiography. *Dentomaxillofac Radiol.* 2004;33:83-6.
  28. Dessoky N, El-Mahallawy M, Fahmy M, Khalil M. Use of custom made peek plates for treatment of mandibular fracture. *Alex Dent J.* 2020.
  29. El-Mahallawy Y, El-Ghamrawy S, Khalil M. The use of Herbert cannulated bone screw in the treatment of mandibular fractures (a clinical and radiographic study). *Alex Dent J.* 2018;43:19-25.
  30. King BJ, Park EP, Christensen BJ, Danrad R. On-Site 3-Dimensional Printing and Preoperative Adaptation Decrease Operative Time for Mandibular Fracture Repair. *J Oral Maxillofac Surg.* 2018;76:1950.e1-e8.
  31. Franco P, Farrell B. Inverted L osteotomy: A new approach via intraoral access through the advances of virtual surgical planning and custom fixation. *Oral Maxillofac Surg Cases.* 2016;2.
  32. Mustafa SF, Evans PL, Bocca A, Patton DW, Sugar AW, Baxter PW. Customized titanium reconstruction of post-traumatic orbital wall defects: a review of 22 cases. *Int J Oral Maxillofac Surg.* 2011;40:1357-62.
  33. Herlin C, Koppe M, Béziat JL, Gleizal A. Rapid prototyping in craniofacial surgery: using a positioning guide after zygomatic osteotomy - A case report. *J Craniofacial Surg.* 2011;39:376-9.
  34. el-mahallawy y, Fahmy MH, Elsheikh SA, ElAshwah Aa. Functional evaluation of computer-assisted mandibular reconstruction with iliac crest bone graft. *Alex Dent J.* 2022:-.
  35. G. Nouredin M, Dessoky N. 3D Printing: Towards the Future of Oral and Maxillofacial Surgery. *Acta Sci Dent Sci.* 2020;4:107-12.
  36. AO Principles of Fracture Management. 2018 2018/05/04. In: AO Principles of Fracture Management [Internet]. Stuttgart: Georg Thieme Verlag KG. Third Edition. Available from: <http://www.thieme-connect.de/products/ebooks/lookinside/10.1055/b-0038-160811>.
  37. Ma J, Ma L, Wang Z, Zhu X, Wang W. The use of 3D-printed titanium mesh tray in treating complex comminuted mandibular fractures: A case report. *Medicine (Baltimore).* 2017;96:e7250.
  38. Schreiber JJ, Anderson PA, Rosas HG, Buchholz AL, Au AG. Hounsfield units for assessing bone mineral density and strength: a tool for osteoporosis management. *J Bone Joint Surg Am.* 2011;93:1057-63.
  39. Hopper KD, Wang MP, Kunselman AR. The use of clinical CT for baseline bone density assessment. *J Comput Assist Tomogr.* 2000;24:896-9.
  40. Feng F, Wang H, Guan X, Tian W, Jing W, Long J, et al. Mirror imaging and preshaped titanium plates in the treatment of unilateral malar and zygomatic arch fractures. *Oral Surg Oral Med Oral Pathol Oral Radiol Endod.* 2011;112:188-94.