

COMPARISON OF AUTOGENOUS FRESH DEMINERALIZED DENTIN AND BETA-TRICALCIUM PHOSPHATE IN IMMEDIATE IMPLANT PLACEMENT OF MANDIBULAR MOLARS (RANDOMIZED CLINICAL CONTROLLED TRIAL)

Ahmed H Abulhassan^{1*} MSc, Osama Sweeden¹ PhD, Gaafar Nabil El-Halawani¹ PhD

ABSTRACT

INTRODUCTION: Autogenous fresh demineralized dentin, a graft used in immediate implant placement, has proven successful. It shares a similar chemical composition to human bone, making it biocompatible and capable of promoting osteoinductive and osteoconductive properties. β -tricalcium phosphate (β -TCP) is a widely employed synthetic bone graft material for filling gaps during immediate implant placement, particularly in posterior molars.

OBJECTIVES: To compare the clinical and radiographic effects of fresh demineralized dentin and β -tricalcium phosphate as graft materials on bone density, crestal bone loss, and implant stability used in alveolar bone regeneration for immediate implant placement in mandibular molars.

MATERIALS AND METHODS: The study included sixteen patients with unrestorable mandibular molars recruited and randomly allocated into two equal groups. The study group received fresh Demineralized Dentin Grafting (DDG), while the control group received β -tricalcium phosphate. All patients were followed clinically and radiologically for six months to assess parameters such as implant stability, crestal bone loss, and bone density.

RESULTS: Crestal bone loss was significantly higher in the β -tricalcium phosphate group compared with the DDG group. Implant stability was significantly higher in the DDG group compared with the β -tricalcium phosphate group; the percentage change of bone density was significantly higher in the DDG group compared with the β -Tri Calcium Phosphate group.

CONCLUSION: Autogenous fresh demineralized dentin may be a more favorable graft material compared to β -tricalcium phosphate for alveolar bone regeneration in immediate implant placement of mandibular molars. Fresh demineralized dentin was associated with superior crestal bone preservation and implant stability outcomes.

KEYWORDS: Immediate Dental Implant, Dentin, Beta-Tricalcium Phosphate.

RUNNING TITLE: Autogenous Fresh Demineralized Dentin and Beta-Tricalcium Phosphate in Immediate Implant Placement of Mandibular Molars: RCT

1 Oral and Maxillofacial Surgery Department, Faculty of Dentistry, Alexandria University

2 Professor of Oral and Maxillofacial Surgery, Faculty of Dentistry, Alexandria University.

3 Lecture at Oral and Maxillofacial Surgery, Faculty of Dentistry, Alexandria University.

* Corresponding Author:

E-Mail: dr.ahmea@gmail.com

INTRODUCTION

Immediate implant placement after a tooth extraction is often considered the optimal procedure; this is because it can trigger the natural healing process, decrease bone loss, eliminate the need for many surgical stages, and, importantly, have a positive emotional and psychological impact on the patient⁽¹⁾.

Patients and clinicians both favor the use of immediate implant insertion (IIP) due to its ability to reduce the duration of treatment and the need for

multiple surgical interventions. Furthermore, placing an implant directly into a fresh extraction socket can reverse the three-dimensional changes in the alveolar process due to tooth extraction⁽²⁾.

However, one limitation of immediate implants is the unavoidable gap or jumping distance between the implant and the socket wall, which can lead to bone resorption and the formation of a bony defect, ultimately reducing implant stability. It is generally recommended to use bone grafts when the jumping distance exceeds 2 mm⁽³⁾.

A wide range of grafting materials is utilized to overcome jumping distance, such as synthetic graft materials and autogenous, allogenic, and xenogenic bone. These materials are carefully chosen to promote osteoblast attachment, proliferation, and differentiation, by effectively binding to the adjacent bone. Additionally, these materials should degrade at an appropriate rate concerning the rate of bone formation⁽⁴⁾.

Alloplasts, such as hydroxyapatite and calcium phosphate bone graft materials, are commonly used due to their high biocompatibility. Representative calcium phosphate graft materials examples include hydroxyapatite (H.A.) and tricalcium phosphate (TCP). These synthetic materials can be produced through various methods, are readily available, and do not carry the risk of spreading disease. Furthermore, their excellent biocompatibility and similarity in structure and chemical composition to the inorganic components of bone make them conducive to bone regeneration⁽⁵⁾.

The inorganic/organic/water ratios of the different components of teeth are as follows: enamel (95% inorganic/0.6% organic/4% water), dentin (70-75% inorganic/20% organic/10% water), and cementum (45-55% inorganic/50-55% organic). When compared to the ratio of alveolar bone (65% inorganic/35% organic/0% water), it becomes evident that dentin, in particular, shares a remarkable chemical similarity with bone. This similarity in the composition may explain the potential of tooth-derived autogenous graft materials to promote bone regeneration and their increasing use in reconstructive surgical procedures⁽⁶⁾.

The tooth, consisting of organic and inorganic components, including various types of calcium phosphate, can also be used as a graft material. The chair-side demineralized dentin approach offers several advantages, such as being created during the same visit, harvested from the same surgical site without additional donor site morbidity, and eliminating the need for additional graft materials, making it a convenient and cost-efficient option for bone regeneration in specific clinical scenarios⁽⁷⁾.

No studies directly compare the use of demineralized dentin as a graft material with β -tricalcium phosphate (β -TCP).

The null hypothesis is there is no difference between the effect of demineralized dentin and β -tricalcium phosphate on peri-implant bone formation around the implants immediately placed in the posterior mandibular molar region.

The purpose of our study was to compare the clinical and radiographic effects of fresh demineralized dentin as autograft and β -tricalcium phosphate as alloplast graft materials on bone density, crestal bone loss, and implant stability used

in alveolar bone regeneration for immediate implant placement in mandibular molars.

MATERIALS AND METHODS

This prospective randomized controlled clinical trial followed a 1:1 allocation ratio and was conducted after obtaining ethical approval from the Research Ethics Committee of Alexandria University Faculty of Dentistry. The study design likely randomly assigned participants to receive either newly demineralized dentin or tricalcium phosphate as bone graft materials following immediate implant placement.

Patients

The study enrolled sixteen patients selected from the outpatient clinic of the oral and maxillofacial surgery department at Alexandria University. These patients had badly destructed mandibular molars that required extraction. Before the procedure, all patients provided informed consent obtained at the Oral and Maxillofacial Surgery Department of Alexandria University's Faculty of Dentistry. The patients were divided into two groups for the study. Group A, the study group, received treatment with fresh demineralized dentin as the bone graft material after immediate implant placement. Group B, the control group, received treatment with β -tricalcium phosphate as the bone graft material after immediate implant placement.

This study's inclusion criteria involved patients with unreconstructable mandibular molars indicated for extraction, with a bony defect around the implant site measuring greater than 2 mm. Patients were required to have good oral hygiene and be adults between the ages of 20-40 years, with no gender preference. Patients with acute infections such as periodontitis or mucosal infections, as well as those with systemic disorders, alcoholism, or smoking history, were excluded from the study.

Materials

- 1-Easy D implant system (General Implants GmbH Germany)
- 2-Hypro-Sorb[®] M collagen membrane (Bioimplon GmbH Germany)
- 3-Adbone[®] TCP(bone graft) granules (Medbone Portugal)
- 4-2% HNO₃ (El-Gomhouria CO., Egypt)
- 5-5% Peracetic acid (El-Gomhouria CO., Egypt)
- 6-70% ethanol (El-Gomhouria CO., Egypt)
- 7-Phosphate buffered saline (El-Gomhouria CO., Egypt)
- 8-Pulverize grinder (Laymax grinder., China)
- 9- Osstell (Osstell, Sweden)

Methods

Preoperative assessment and examinations

Clinical examination

Complete medical and dental histories were taken, followed by extra-oral and intra-oral inspection to detect dental caries, periodontal disease, and dental

infection. The tooth to be replaced was examined to ensure the absence of acute infection.

Radiographic examination

Cone Beam Computed Tomography (CBCT) was done for virtual treatment planning, including the implant's position, length, and diameter.

Oral preparation: Scaling was done, and oral hygiene instructions were given to the patients.

Surgical phase

Preoperative medications: All patients were rinsed with chlorohexidine (Hexitol 125mg/100ml, concentration 0.125%: Arabic drug company, ADCO) antiseptic mouthwash for thirty seconds before the operation.

Surgical procedure

The operation was performed under local anesthesia (Mepivacaine hydrochloride 2 with epinephrine 1:100,000). Dental implants were placed using a hand and torque wrench then the cover screw was attached. Atraumatic extraction of the mandibular molar remaining root or tooth was performed, followed by Drilling sequentially according to manufacturer instructions.

For group A, a fresh demineralized dentin graft was prepared, placed around the implant bone graft, and applied into the socket. For group B, β -tricalcium phosphate graft was placed around the implant. Hypro-SorbM collagen membrane was used to cover the bone graft, and a flap was released from the buccal flap with an undermining incision. Non-resorbable 3/0 silk suture material was used to stitch the surgical wound.

Fresh Demineralized Dentin Preparation

Restorations, Caries, cementum, periodontal ligament, and pulp tissue were removed, 0.3 mm holes were made along the entire tooth surface using 330 burs, then the tooth was a grind for 3 to 10 seconds using Pulverize grinder. The tooth particles were sieved (Gilson stainless steel wire sieve) to particles size 300 to 1200 microns, then sorted particles were immersed in 70 % ethanol and 5% Peracetic acid in a sterile container for 10 minutes to remove any soft tissue remnants, bacteria, and smear layer (defatting and sterilization). The tooth particles were demineralized using 2% HNO₃ for 20 minutes to expose the dentin organic matrix. The particulate dentin was washed with phosphate-buffered saline twice for 5 minutes to restore the pH balance to 7.4 (Figure 1).




Figure (1): Demineralized Dentin preparation a) extracted tooth preparation, b) after cleaning and removing enamel and cementum, c) tooth will be grind for 3 to 10 seconds, d) particles sieved, e) particles immersed in 70 % ethanol and 5% Peracetic acid, f) demineralization using 2% HNO₃ for 20 minutes, g) wash with phosphate buffered saline twice, h) demineralized dentin is ready.

Postoperative phase

The patients were monitored for 24 hours and then reviewed after one and twelve weeks postoperatively. Sutures were removed after seven days.

Postoperative medications

All patients were given a 5-days course of systemic antibiotics; Amoxicillin + clavulanate 1 gm tablets (Augmentin 1 g, GlaxoSmithKline, U.K.) twice daily for the next six days. Ibuprofen 400 mg tab (Brufen400mg: Abbott-U.S) every eight hours for four days and Chlorhexidine (Hexitol 125mg/100ml, concentration 0.125%: Arabic drug company, ADCO) antiseptic mouthwash. Patients were instructed to apply cold packs for 5-10 minutes every 2-3 hours on the first day, warm mouthwash every 6 hours for the following days, and oral hygiene instructions.

Clinical follow-up

Implant stability

The implant stability quotient was assessed using OSSTELL at immediate postoperative and after six months⁽⁸⁾.

Radiological follow-up

The CBCT scans were conducted immediately postoperatively and at six months postoperatively to evaluate:

A. Peri-implant bone density

Peri-implant bone density was measured at eight fixed points around the implant, and the mean was calculated using an On-Demand 3D (On Demand 3D Cybermed South Korea) scan program⁽⁹⁾.

B. Crestal Bone loss

The distance between the implant platform and the first implant-to-bone contact was measured using the ruler tool of the on-demand software on the mesial and distal aspects of the implant, and the mean was calculated⁽⁹⁾.

Prosthetic phase

The final prosthesis was a porcelain fused metal crown inserted six months postoperatively.

Statistical analysis

The collected data were analyzed using the Statistical Package for Social Science (SPSS) program for statistical analysis (ver 25)⁽¹⁰⁾. Data were described using minimum, maximum, mean, standard deviation, 95% CI of the mean, median, 95% CI of the median, 25th-75th percentile, and inter-quartile range⁽¹¹⁾. Comparisons were carried out between two studied independent, not-normally

distributed subgroups using the Mann-Whitney U test⁽¹²⁾. Comparisons were carried out between two studied related, not-normally distributed subgroups using the Wilcoxon Signed Ranks test⁽¹³⁾. During sample size calculation, beta error accepted up to 20% with a power of study of 80%. An alpha level was set to 5% with a significance level of 95%. Statistical significance was tested at p -value $<.05$ ⁽¹⁴⁾.

RESULTS

Biodata

The study included sixteen patients. Their age ranged between 20-40 years, with a mean of 31.63 ± 6.05 years for group A (study group) and 34.88 ± 5.33 for group B (control group). In the demineralized dentin graft group, there were 4 (50.00%) males and 4 (50.00%) females, while in the β -tri calcium phosphate group, there were 5 (62.50%) males and 3 (37.5%) females. There was no statistically significant difference in the distribution of sex between the two groups ($p=.614$). The implant stability ISQ immediately postoperative was not statistically significantly different between the Demineralized Dentin Graft group (64.25 ± 3.01) and the β -Tri Calcium Phosphate group (66.50 ± 2.98) ($p=.100$). Six months postoperatively implant stability was statistically significantly higher in the Demineralized Dentin Graft group (80.00 ± 6.09) compared with the β -Tri Calcium Phosphate group (70.00 ± 2.73) ($p=.002$). Also, the percentage change of ISQ was statistically significantly higher in the Demineralized Dentin Graft group (24.52 ± 7.59) compared with the β -Tri Calcium Phosphate group (5.300 ± 1.76) ($p=.001$) (Table I).

The bone density immediately postoperative was statistically significantly lower in the Demineralized Dentin Graft group (806.75 ± 143.96) compared with the β -Tri Calcium Phosphate group (1195.00 ± 79.64) ($p=.001$); also at six months postoperatively (939.38 ± 123.58) and (1276.13 ± 50.33); respectively ($p=.001$); But the percentage change of bone density was statistically significantly higher in the Demineralized Dentin Graft group (17.60 ± 8.69) compared with the β -Tri Calcium Phosphate group (6.97 ± 3.40) ($p=.001$) (Table II).

The Crestal Bone Loss in the β -Tri Calcium Phosphate group (0.45 ± 0.19) was statistically significantly higher compared with the demineralized dentin graft group (0.21 ± 0.15) at six months postoperatively ($p=.015$) (Table III).

Figure 2 and 3 demonstrates the radiographic and surgical steps.

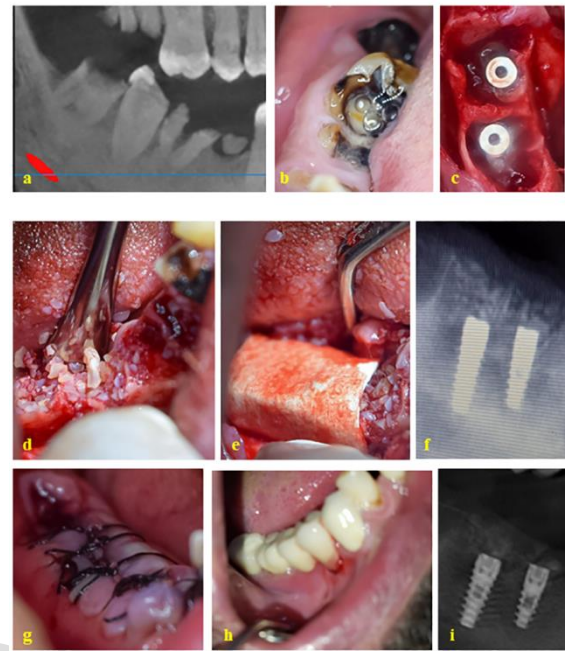


Figure (2): Radiographic and surgical steps for patient in demineralized dentin graft group a) Preoperative X-ray, b) preoperative clinical view, c) flap raising and implant placement, d) graft placing, e) membrane placing, f) immediate postoperative x ray, g) suturing and flap closing h) final prosthesis after 6 months, i) postoperative X ray after 6 months

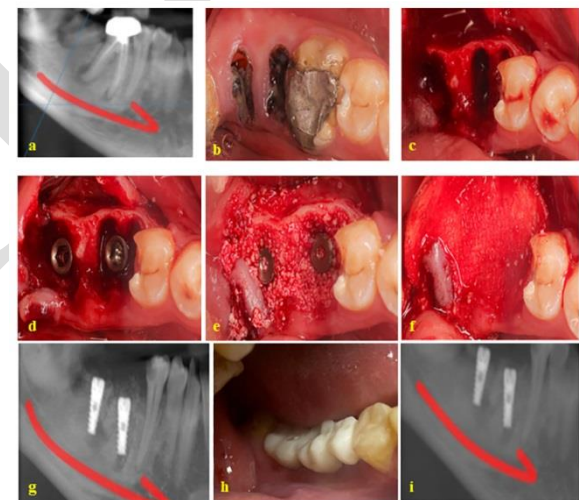


Figure (3): Radiographic and surgical steps for patient in Beta-Tri-calcium phosphate group a) Preoperative X-ray, b) preoperative clinical view, c) extraction and retraction of buccal flap, d) implant placement, e) graft placing, f) membrane placing, g) immediate postoperative x ray h) final prosthesis after 6 months, i) postoperative X ray after 6 months

Table (I): Comparison of the Implant Stability (ISQ) at different times of measurements in the two studied groups

Implant Stability (ISQ)	Group		Test of significance <i>p</i>
	Demineralized Dentin Graft (n=8)	β-Tri Calcium Phosphate (n=8)	
Immediate postoperatively - Min. – Max. - Mean ± SD - Median - 95% CI of the median	60.00-69.00 64.25±3.01 63.50 62.50-66.50	64.00-72.00 66.50±2.98 65.00 65.00-72.00	$Z_{(MW)}=1.646$ $p=.100$ NS
Six months postoperatively - Min. – Max. - Mean ± SD - Median - 95% CI of the median	73.00-92.00 80.00±6.09 79.50 75.00-85.00	67.00-75.00 70.00±2.73 69.50 68.00-73.00	$Z_{(MW)}=3.162$ $p=.002^*$
Test of significance <i>p</i>	$Z_{(WSR)}=2.585$ $p=.010^*$	$Z_{(WSR)}=2.565$ $p=.010^*$	
ISQ percentage change (%) - Min. – Max. - Mean ± SD - Median - 95% CI of the median	16.18-41.54 24.52±7.59 22.43 20.63-26.98	4.17-9.38 5.30±1.76 4.62 4.48-9.38	$Z_{(MW)}=3.363$ $p=.001^*$

n: Number of patients, Min-Max: Minimum – Maximum, S.D.: Standard Deviation, CI: Confidence interval, Z: Z test of Mann-Whitney U test, *: Statistically significant ($p<.05$), NS: Statistically not significant ($p>.05$), WSR: Wilcoxon Signed Ranks Test

Table (II): Comparison of the Bone Density (H.U.) at different times of measurements in the two studied groups

Bone Density (H.U.)	Group		Test of significance <i>p</i>
	Demineralized Dentin Graft (n=8)	β-Tri Calcium Phosphate (n=8)	
Immediate Postoperative - Min. – Max. - Mean ± SD - Median - 95% CI of the median	559.00-978.00 806.75±143.96 852.00 628.00-905.00	1100.00-1290.00 1195.00±79.64 1200.00 1110.00-1270.00	$Z_{(MW)}=3.361$ $p=.001^*$
Six months postoperatively - Min. – Max. - Mean ± SD - Median - 95% CI of the median	744.00-1100.00 939.38±123.58 986.00 786.00-1028.00	1210.00-1340.00 1276.13±50.33 1293.50 1217.00-1317.00	$Z_{(MW)}=3.161$ $p=.001^*$
Test of significance <i>p</i>	$Z_{(WSR)}=2.521$ $p=.012^*$	$Z_{(WSR)}=2.521$ $p=.012^*$	
Six months Postoperatively vs. immediate postoperative percentage change (%) - Min. – Max. - Mean ± SD - Median - 95% CI of the median	10.72-33.09 17.60±8.69 12.12 11.38-25.16	2.91-11.30 6.97±3.40 6.17 3.88-10.81	$Z_{(MW)}=3.151$ $p=.002^*$

n: Number of patients, Min-Max: Minimum – Maximum, S.D.: Standard Deviation, CI: Confidence interval, Z: Z test of Mann-Whitney U test, *: Statistically significant ($p<.05$), NS: Statistically not significant ($p>.05$), WSR: Wilcoxon Signed Ranks Test

Table (III): Comparison of the Crystal Bone Loss (mm) after six months postoperatively in the two studied groups

Crystal Bone Loss (mm) (6 months postoperatively)	Group		Test of significance <i>p</i>
	Demineralized Dentin Graft (n=8)	β-Tri Calcium Phosphate (n=8)	
- Min. – Max. - Mean ± SD - Median - 95% CI of the median	0.10-0.50 0.21±0.15 0.15 0.10-0.30	0.25-0.70 0.45±0.19 0.40 0.30-0.70	$Z_{(MW)}=2.421$ $p=.015^*$

n: Number of patients, Min-Max: Minimum – Maximum, S.D.: Standard Deviation, CI: Confidence interval
Z: Z test of Mann-Whitney U test, *: Statistically significant ($p<.05$), NS: Statistically not significant ($p>.05$)

DISCUSSION

In the present study, the implant stability (ISQ), immediately and six months postoperatively, was significantly higher in the demineralized dentin graft group compared with the β-tri calcium phosphate group ($p=.003$; $p=.002$; respectively). The percentage increase in implant stability in the demineralized dentin graft group was statistically significantly higher than in the β-tri calcium phosphate group ($p<.001$). The percentage increase in the demineralized dentin graft group was more than 20%, which agrees with that reported by El-Said et al.⁽¹⁵⁾, in their single-arm clinical trial, who reported a 15% increase in the mean OSSTELL score at six months postoperatively in comparison to the time of implant placement. Rawat et al. (12),⁽¹⁶⁾ reported that β-TCP appears unsuitable and not advantageous as a bone filler in immediate implant placement due to its slow bone formation and integration and inability to condense appropriately. They also added that a 3-month follow-up period is insufficient to evaluate the clinical advantages of using β-TCP as a defect filler around the implant fixture to enhance osseointegration. However, a larger sample size and a longer follow-up duration are required for a more comprehensive assessment. Although our study increased the follow-up period to 6 months, the demineralized dentin graft group was superior to the β-tri calcium phosphate group. Also, the level of Bone Density, immediately and six months postoperatively, was significantly lower in the demineralized dentin graft group compared with the β-tri calcium phosphate group ($p=.001$; $p=.001$; respectively). This difference is not clinically significant due to the nature of the β-tri calcium phosphate, which has a higher density than natural bone and demineralized dentin. β-TCP is attributed to the substantial release of calcium (Ca^{2+}) and sulfate (SO_4^{2-}) ions. These inorganic salts are crucial for new bone formation and

contribute to increased bone density⁽¹⁷⁾. But, the percentage increase in bone density in the demineralized dentin graft group was statistically significantly higher than in the β -tri calcium phosphate group ($p=.002$).

β -TCP can partially integrate into natural bone tissue, is osteoconductive, and has a high affinity for proteins, such as BMPs, which can induce stem cell differentiation and growth, causing new bone formation. β -TCP is easily resorbable, and together with its interconnected porous structure, it is rapidly replaced by new bone⁽¹⁸⁾.

Autogenous Fresh Demineralized Dentin (ADDM) promotes osteogenesis through both endochondral and intramembranous bone formation mechanisms because ADDM contains native growth factors that support the attachment of mesenchymal cells and can absorb various proteins derived from body fluids⁽⁶⁾.

The percentage increase in bone density in the present study is more than 15% in the demineralized dentin graft group and about 7% in the β -TCP. El-Said et al.⁽¹⁵⁾ reported a 39% increase in mean bone density six months after implant placement compared to preoperative values. Radiographic examination showed that all implants were fully osseointegrated with no signs of bone resorption. The difference between these two studies may be because the El-Said et al.⁽¹⁵⁾ was carried out on the maxilla, and the present study in the mandible

In agreement with our study, a randomized controlled trial by Daif (2013)⁽¹⁹⁾ showed a significant increase in bone density measurements from 3 to 6 months in the group treated with pure phase multiparous b-TCP.

In the present study, the Crestal Bone Loss after six months postoperatively was statistically significantly higher in the β -TCP group compared with the demineralized dentin graft group ($p=.015$); this could be explained by the fact that the ADDM represents an efficient carrier of different bioactive growth factors (G.F.s), such as Bone Morphogenic Proteins (BMPs) and transforming growth factor- β (TGF- β). Such GFs that have been proved to be present in the dentin are involved in the repairing process of the bone, thus potentially enhancing the bone healing processes⁽²⁰⁾. When BMPs are used alone, they cannot show osteoinductive effects due to their high solubility.

The crestal bone loss six months postoperatively in the present study was statistically significantly higher in the b-TCP group (0.45 ± 0.19) compared with the demineralized dentin group (0.21 ± 0.15) ($p=.015$). El-Said et al.⁽¹⁵⁾, who used a demineralized dentin graft, reported that the mean bone loss around implants in six months postoperatively was $0.45 \text{ mm} \pm 0.14$.

Rawat et al. (12),⁽¹⁶⁾ found that the mean mesial crestal bone loss was 0.60 mm and the mean distal crestal bone loss to be 0.4 mm. In a short-term follow-up of the same patients, the mean crestal bone loss was similar to the annual loss of crestal bone seen in normal healing extraction sockets (0.8-1mm). However, after 12 months of follow-up, it was observed that there was a gain in crestal height by 0.25mm on the mesial side and a loss of 0.48mm on the distal side, as compared to the original recorded crestal height.

Uppala S et al. (2020)⁽²¹⁾ compared the crestal bone loss around dental implants using tricalcium phosphate with and without platelet-rich plasma. They reported that the average crestal bone loss 9 months after the implants placement was 2.75 mm and 2.23 mm; respectively, being statistically significantly higher in the group with platelet-rich plasma. They concluded that β -TCP is a promising biomaterial for clinical situations requiring bone augmentation.

Peng Li et al. (2018)⁽²²⁾ (23), evaluated the clinical efficacy of autogenous Demineralized Dentin Matrix (DDM) versus Bio-Oss granules in guided bone regeneration (GBR) for immediate implantation in periodontal post-extraction sites. They found no statistically significant difference between the two groups in implant stability quotient values and marginal bone resorption. They concluded that the autogenous DDM granules prepared at the chairside after extractions could be an excellent, readily available alternative to bone graft material in GBR, even for the implantation of severe periodontitis cases.

Harel N et al. (2013)⁽²³⁾ conducted a retrospective chart review of all patients who underwent implant placement therapy between years 1998 and 2000 to assess the long-term results of implants immediately placed into fresh extraction sockets and grafted with b-TCP. The authors concluded that comparisons of groups (immediate implantation + β -TCP), (delayed implantation with β -TCP), and (delayed implantation) did not show a statistically significant difference regarding the amount of bone loss after 10 years of follow-up.

In 2012, a randomized clinical trial was carried out by Barone et al.⁽²⁴⁾ to evaluate and compare implants placed in augmented versus non-augmented extraction sockets. They found that the average crestal bone loss at 3 years of follow-up was $1.02 \pm 0.3 \text{ mm}$ for the group without alveolar conservation and $1.00 \pm 0.2 \text{ mm}$ for the group with tooth sockets preserved using dentin derivative graft; the authors reported no significant differences in the marginal bone loss between the two groups at 1 year, 2 years or 3 years.

Starch-Jensen et al. (2022)⁽²⁵⁾ in a systematic review aimed to evaluate the current knowledge of implant treatment outcome following lateral

alveolar ridge augmentation with autogenous tooth block graft compared with autogenous bone block graft prior to implant placement, concluded that lateral alveolar ridge augmentation with tooth block seems to be a suitable alternative to bone block.

CONCLUSIONS

The findings of this study suggest that autogenous fresh demineralized dentin may be a more favorable graft material compared to β -tricalcium phosphate for alveolar bone regeneration in immediate implant placement of mandibular molars. The use of fresh demineralized dentin was associated with superior outcomes in terms of crestal bone preservation, implant stability

CONFLICT OF INTEREST

The authors declare that they have no conflicts of interest.

FUNDING STATEMENT

The authors received no specific funding for the conduction of this study.

REFERENCES

1. Sanz I, Garcia-Gargallo M, Herrera D, Martin C, Figuero E, Sanz M. Surgical Protocols for Early Implant Placement in Post-Extraction Sockets: A Systematic Review. *Clinical oral implants research* 2012;23:67-79.
2. Cosyn J, De Lat L, Seyssens L, Doornewaard R, Deschepper E, Vervaeke S. The Effectiveness of Immediate Implant Placement for Single Tooth Replacement Compared to Delayed Implant Placement: A Systematic Review and Meta-Analysis. *Journal of Clinical Periodontology* 2019;46:224-41.
3. Kabi S, Kar R, Samal D, Deepak KC, Kar IB, Mishra N. Immediate Dental Implant Placement with or without Autogenous Bone Graft: A Comparative Study. *National Journal of Maxillofacial Surgery* 2020;11(1):46.
4. Yip I, Ma L, Matheos N, Dard M, Lang NP. Defect Healing with Various Bone Substitutes. *Clinical oral implants research* 2015;26(5):606-14.
5. Yoo H-S, Bae J-H, Kim S-E, Bae E-B, Kim S-Y, Choi K-H, et al. The Effect of Bisphasic Calcium Phosphate Block Bone Graft Materials with Polysaccharides on Bone Regeneration. *Materials* 2017;10(1):17.
6. Kim Y-K, Lee J-H, Um I-W, Kim K-W, Murata M, Akazawa T, et al. Tooth-Derived Bone Graft Material. *Journal of Korean Association of Oral and Maxillofacial Surgeons* 2013;39(3):103-11.
7. Eaton LA. Consort Guidelines. In: Gellman MD, editor. *Encyclopedia of Behavioral Medicine*: Springer; 2020.
8. Aguilar-Salvatierra A, Calvo-Guirado JL, González-Jaranay M, Moreu G, Delgado-Ruiz RA, Gómez-Moreno G. Peri-Implant Evaluation of Immediately Loaded Implants Placed in Esthetic Zone in Patients with Diabetes Mellitus Type 2: A Two-Year Study. *Clinical oral implants research* 2016;27(2):156-61.
9. Zhou D, Yao L, Guo K, Lu C. Cytogenetic Evaluation of Cataract Patients Occupationally Exposed to Ionizing Radiation in Northeast China. *Genet Mol Res* 2016;15(3).
10. IBM Corp. *Ibm Spss Statistics for Windows, Version 25.0*. Armonk, NY: IBM Corp.; Released 2017.
11. Greenland S, Senn SJ, Rothman KJ, Carlin JB, Poole C, Goodman SN, et al. *Statistical Tests, P Values, Confidence Intervals, and Power: A Guide to Misinterpretations*. *European Journal of Epidemiology* 2016;31(4):337-50.
12. Mann HB, Whitney DR. On a Test of Whether One of Two Random Variables Is Stochastically Larger Than the Other. *The Annals of Mathematical Statistics* 1947:50-60.
13. Wilcoxon F. Individual Comparisons by Ranking Methods. *Biometrics bulletin* 1945;1(6):80-3.
14. Curran-Everett D. *Evolution in Statistics: P Values, Statistical Significance, Kayaks, and Walking Trees*. American Physiological Society Bethesda, MD; 2020. p. 221-4.
15. El-Said MM, Sharara AA, Melek LF, Khalil NM. Evaluation of Autogenous Fresh Demineralized Tooth Graft Prepared at Chairside for Dental Implant (Clinical and Histological Study). *Alexandria Dental Journal* 2017;42(1):47-55.
16. Rawat S, Singh P. Efficacy of the B-Tricalcium Phosphate in the Stability of Immediate Implant Placement-an Original Research. *International Journal of Psychosocial Rehabilitation* 2020;24(06).
17. Schmidlin PR, Jung RE, Schug J. Prevention of Alveolar Ridge Resorption after Tooth Extraction-a Review. *Schweizer Monatsschrift fur Zahnmedizin= Revue mensuelle suisse d'odontostomatologie= Rivista mensile svizzera di odontologia e stomatologia* 2004;114(4):328-36.
18. Roca-Millan E, Jané-Salas E, Mari-Roig A, Jiménez-Guerra Á, Ortiz-García I, Velasco-Ortega E, et al. The Application of Beta-Tricalcium Phosphate in Implant Dentistry: A Systematic Evaluation of Clinical Studies. *Materials* 2022;15(2):655.
19. Daif ET. Effect of a Multiporous Beta-Tricalcium Phosphate on Bone Density around Dental Implants Inserted into Fresh Extraction Sockets. *Journal of Oral Implantology* 2013;39(3):339-44.

20. Taschieri S, Morandi B, Alberti A, Tarasenko S, Diachkova E, Francetti L, et al. Immediate Implant Positioning Using Tooth-Derived Bone Substitute Material for Alveolar Ridge Preservation: Preliminary Results at 6 Months. *Clinical and Experimental Dental Research* 2023;9(1):17-24.
21. Uppala S, Parihar AS, Modipalle V, Manual L, Oommen VM, Karadiguddi P, et al. Crestal Bone Loss around Dental Implants after Implantation of Tricalcium Phosphate and Platelet-Rich Plasma: A Comparative Study. *Journal of family medicine and primary care* 2020;9(1):229.
22. Li P, Zhu H, Huang D. Autogenous Ddm Versus Bio-Oss Granules in Gbr for Immediate Implantation in Periodontal Postextraction Sites: A Prospective Clinical Study. *Clinical implant dentistry and related research* 2018;20(6):923-8.
23. Harel N, Moses O, Palti A, Ormianer Z. Long-Term Results of Implants Immediately Placed into Extraction Sockets Grafted with B-Tricalcium Phosphate: A Retrospective Study. *Journal of oral and maxillofacial surgery* 2013;71(2):e63-e8.
24. Barone A, Orlando B, Cingano L, Marconcini S, Derchi G, Covani U. A Randomized Clinical Trial to Evaluate and Compare Implants Placed in Augmented Versus Non-Augmented Extraction Sockets: 3-Year Results. *Journal of periodontology* 2012;83(7):836-46.
25. Starch-Jensen T, Vitenson J, Deluiz D, Østergaard KB, Tinoco EMB. Lateral Alveolar Ridge Augmentation with Autogenous Tooth Block Graft Compared with Autogenous Bone Block Graft: A Systematic Review. *Journal of Oral & Maxillofacial Research* 2022;13(1).