

EVALUATION OF COMPUTER ASSISTED DESIGN COMPUTER ASSISTED MANUFACTUREING (CAD/CAM) OSTEOTOMY GUIDE IN BILATERAL MANDIBULAR SAGITTAL SPLIT OSTEOTOMY (A RANDOMIZED CONTROLLED CLINICAL TRIAL)

Ahmed E. Shararah^{1*} *MSc*, Ahmed A. Sharara² *PhD*, Samraa A. Elsheikh ²*PhD*,
Adham A. EL-Ashwah² *PhD*, Marwa G. Noreldien³ *PhD*

ABSTRACT

INTRODUCTION: The introduction of CAD/CAM technology in orthognathic surgery planning has facilitated the procedure and enabled more predictable results. This study was designed to introduce and evaluate the clinical use of a CAD/CAM surgical guide for bilateral sagittal split osteotomy (BSSO) in the correction of dentofacial deformity cases with skeletal class 2 or 3.

AIM OF THE STUDY: To evaluate the efficiency of guided osteotomy in orthognathic surgery. **Materials and Methods:** This study was conducted on 20 patients who underwent bilateral sagittal osteotomy (BSO) procedures. Ten patients (the control group) were treated with the conventional method, without an osteotomy guide. The other 10 patients (the study group) were treated with a CAD/CAM bone-borne guide.

Postoperative patient evaluation was performed clinically by comparing the operation time post operative pain and sensory nerve involvement at 1 week, 2 weeks, and 3 months. Radiographic evaluation was performed by computed tomography (CT) at 1 month postoperatively.

RESULTS: The surgical outcome revealed the satisfactory correction of their skeletal deformity. The study group showed significantly better results than control group concerning operation time, Visual Analogue Scale, and sensory nerve involvement ($p \leq 0.05$.)

CONCLUSION: Within the limitations of this study, it can be considered that CAD/CAM osteotomy guide for BSSO is superior to non-guided BSSO regarding the operation time and sensory nerve involvement.

KEYWORDS: (CAD/CAM), VSP, BSSO.

RUNNING TITLE: Guided versus conventional osteotomy in BSSO.

1 MSc Faculty of Dentistry Alexandria University

2 Professor of Oral and Maxillofacial Surgery Department, Faculty of Dentistry, Alexandria University, Alexandria, Egypt

3 Assistant Professor of Oral and Maxillofacial Surgery Department, Faculty of Dentistry, Alexandria University, Alexandria, Egypt

* *Corresponding Author:*

E-mail: a7med.dentist@yahoo.com

INTRODUCTION

Orthognathic surgery is a unique endeavor in facial surgery. In cases with severe Class III occlusion or patients with syndromic or facial clefts, this surgery may be performed for functional or growth-related reasons (1). Orthognathic surgery is the surgical adjustment of the mandible or maxilla that results in the right alignment and placement of the bones and teeth with respect to the base of the skull. For individuals with dentofacial deformity, orthognathic surgery combined with orthodontic therapy effectively corrects malocclusion (2).

The presenting facial disproportion will have at least some negative effects on psychosocial health (3).

The definitions of acceptable levels of deviation from normal continue to be debated by professionals and patients alike (4). The National Center for Health Statistics has collected data over the years, and the Research Council has conducted multidisciplinary seminars to draw attention to these issues (5).

Surgery to reposition the jaws (i.e., orthognathic surgery) as part of an interdisciplinary approach is

often recommended to manage the related skeletal, dental, and soft-tissue dysfunctions and concerns (6). The surgical management should be in harmony with speech therapy, dental work, and orthodontics (7).

Orthognathic surgery involves repositioning the maxillary or mandibular teeth-bearing segments in different directions of space (vertical, sagittal, or transverse) in relation to the craniofacial complex (8).

Sagittal split-ramus osteotomy (SSRO), intraoral vertical ramus osteotomy (IVRO), and intraoral inverted "L" osteotomy (IVLO) are three popular surgical procedures used to manage mandibular deformity (9). Overall, when performed by a well-trained, experienced surgeon in a center that conducts a significant volume of such cases, orthognathic surgical treatment is safe (10).

Preoperatively, mock surgery is planned and simulated either on models or virtually. Conventional planning, requires multiple steps from making impressions and models, bite registration, face-bow record, mounting, marking, and sawing the casts, measuring the amount of desired movement, simulating the surgery using a fully adjustable articulator, fabrication of intermediate splint and fabrication of the final splint (11, 12).

Since the introduction of the composite virtual models in 2003 (13), different computer programs became available to virtually simulate orthognathic surgery, predict postoperative soft tissue contours and fabricate the intermediate and final splints by 3D printing technology.

In comparison to traditional planning, virtual surgical planning has been revealed to be more accurate and easier (12).

Recent advancements in virtual surgical planning (VSP) and computer-assisted designed and computer assisted manufactured (CAD/CAM) technology have improved preoperative planning. Also, it facilitated the preparation of surgical splints, and proved highly accurate compared with standard methods (14).

The aim of study was to evaluate the effectiveness of CAD/CAM guided osteotomy in BSSO with regards to operation time and sensory nerve involvement. The null hypothesis of the study stated that there was no significant difference between CAD/CAM osteotomy guide for BSSO and non-guided BSSO regarding operation time and sensory nerve involvement.

MATERIALS AND METHODS

This study was a randomized controlled clinical trial with two groups (Study group and control group) with 1:1 allocation ratio. This study was reported according to CONSORT guidelines. (<http://www.consort-statement.org>). Prior to the procedure, all patients signed an informed consent form at Alexandria University's Faculty of Dentistry's Oral and Maxillofacial Surgery. This research was approved by the Ethics Committee, Faculty of Dentistry, Alexandria University (Ethics Committee Number 0406-03/2022).

Patients were treated at the outpatient clinics of the Department of Oral and Maxillofacial Surgery, Faculty of Dentistry, Alexandria University from January 2022 to February 2023.

Sample size (15) was calculated using Power Analysis and Sample Size Software (PASS 2020) "NCSS, LLC. Kaysville, Utah, USA, ncss.com/software/pass". A minimal total hypothesized sample size of 16 eligible participants admitted and selected by both the outpatient clinic of Oral and Maxillofacial Surgery Department and Orthodontics Department, Faculty of Dentistry, Alexandria University. Each group required eight patients to evaluate the efficiency of CAD CAM guided osteotomy in BSSO with regards to sensory nerve involvement and the operation time; taking into consideration 95% confidence level and 80% power using Chi Square-test. Drop out estimate was calculated to be 10% of the whole sample, thus the total sample is supposed to be 20 (10 per group).

The twenty patients were randomly allocated into two equal groups (10 patients per group); a study group and a control group (Simple randomization). Each patient was given a serial number in a sealed opaque envelope. All numbers were submitted in the website Randomizer.org. Computed Generated Randomization table was used to specify which serial number belonged to which group. As a result, the participants were blinded to which group they belonged to (16).

Inclusion criteria were patients aged from 20 to 40 years and all patients requiring bilateral sagittal split osteotomy were selected including those suffering from skeletal malocclusion (Class II or Class III) (17)

Patients were excluded if they were suffering from cleft lip and palate, skeletal disharmony due to trauma, severe facial asymmetry and systemic conditions that may contraindicate the surgery (18).

The Primary objective was to evaluate the effectiveness of CAD/CAM guided osteotomy in BSSO with regards to operation time and sensory nerve involvement.

The Secondary objective was to evaluate radiographically the expected corrected position of the mandible in relation to the preoperative virtual planning using CT.

Materials

Piezotome (Cube Acteon), piezotome bone surgery kit, standard 2.0mm mini plates, mono-cortical screws measuring 2.0mm in diameter and 5-7mm in length (Stema Medizintechnik GmbH, Stockach, Germany), Orthognathic surgical instruments set, CT (a slice thickness of 0.5 mm) and CAD-CAM surgical guide (Figure 1)

Surgical procedure

Preoperative assessment

Pre-operative assessment and examinations

Full medical and dental histories were taken followed by extra-oral and intra-oral inspection to

confirm the facial asymmetry, malocclusion and via palpation to assess any tenderness, teeth mobility, condylar stability.

A thorough diagnostic examination was done including detailed collection of preoperative records, including clinical photographs, cephalometric analysis, stone and digital laser-scanned dental models, and centric relation (CR) bite registered in an upright position (occlusal splint).

Patients underwent all the necessary laboratory investigations to obtain clearance for operation from the anesthesia specialist. They were instructed to fast at least 8 hours prior to the surgery.

Radiographic examination

Computerized tomography (CT) was performed for all patients for the purpose of diagnosis and treatment planning.

For the study group: guide was manufactured using CAD technologies after conventional digital planning of BSSO on Proplan software (**Figure 2**). The occlusal wafer and the osteotomy guide were fabricated using stereolithography form 3B+3D printer and mimics software.

Preoperative preparations

Preoperative placement of orthodontic brackets on the teeth with scaling and root planning for all patients and oral hygiene instruction was given.

Surgical procedure

All operations were performed by the same surgeon. The operation was performed under general anesthesia with nasotracheal intubation and in supine position. Intraoral and extraoral scrubbing with povidone iodine was done followed by draping with sterile towels, exposing only the area of surgery.

A mucoperiosteal intra-oral vestibular incision at the retromolar region was done and subperiosteal dissection exposed the anterior aspect of the lateral ramus and the posterior body of the mandible down to the inferior border. Dissection was carried down to the inferior border of the mandibular body and the posterior border of the ramus. A J-stripper was then inserted along the inferior border of the mandible and all attachments were released. A V-shaper retractor was then placed along the external oblique ridge and all attachments to the anterior ramus were released as superior onto the coronoid as possible. A Kocher clamp with a chain was then placed on the coronoid process and secured to the surgical drape. Subperiosteal dissection was continued along the internal oblique ridge inferior to the level of the occlusal plane to allow visualization of the medial aspect of the ramus.

The osteotomy was done as following:

In the control group

A small elevator was placed along the medial aspect of the ramus and was utilized to retract and protect the pedicle. The lingula was typically located 1 cm

above the occlusal plane and between one-half to two-thirds the distance from anterior to posterior on the ramus. Once the pedicle was adequately protected, a channel retractor was inserted to provide lateral retraction, a Kocher was placed to provide superior retraction, and piezotome bone surgery BS1S tip was placed medial to the ascending ramus, superior to the lingula and parallel to the occlusal plane to make the medial cut. The cut was made through the cortical bone and into the cancellous bone, and then the cutting tip was turned and the cut continued anteriorly down the external oblique ridge to the level of the second molar. The final cut was then made vertically along the buccal cortex at the level of the second molar down to the inferior border of the mandible. All of the cuts were then checked to ensure that they were complete through the cortex and down to cancellous bone.

In the study group

After the tissue reflection the resin guide was placed and fixed in place using titanium screw.

The medial, sagittal and lateral osteotomy cuts were made using a piezotome tip guided by the osteotomy guide. Then the guide was removed, and the cuts were then checked to ensure that they were complete through the cortex and down to cancellous bone (**Figure 3**).

The steps of Splitting

To start splitting, a narrow spatula chisel was placed in the vertical cut from upward direction and malleted downward to initiate splitting at the inferior border of the mandible. Next the spatula chisel was malleted through the horizontal osteotomy to separate the segments at the horizontal cut. Splitting was continued from the vertical cut to the horizontal one using two spatula chisels. After chiseling the whole length of the osteotomy line, a large Obwegeser's osteotome was used into the separation line, usually this maneuver resulted in separation of the segments by one or two firm strokes to split the segments.

After splitting, the proximal segment was examined to assure that the condyle remained in the proximal segment. The distal segment was examined for the integrity of the neurovascular bundle (**Figure 4**). Then the mandible was placed in its desired position with the aid of the prefabricated splint and any intervening bone was removed. The two segments were then fixed according to the surgeon's preference with titanium miniplate (**Figure 5**). The occlusion was checked to ensure that it was satisfactory. If the desired occlusion had been reached, the incisions were closed with absorbable suture vicryl 3-0 following copious irrigation and hemostasis. Guiding elastics were placed intraoperatively.

Postoperative instructions

All patients were instructed to apply ice pack extra-orally starting immediately postoperatively for 12 hours. Patients were given strict instructions to maintain proper oral hygiene. In addition to eating a soft diet for 2 weeks postoperatively.

Postoperative medications

All patients were given a 5-days course of systemic antibiotics; Amoxicillin + clavulanate 1 gm tablets (Augmentin 1 g, GlaxoSmithKline, UK) twice daily for 7 days starting on the day of surgery. Diclofenac potassium 50mg tab (Cataflam50mg: Novartis-Switzerland) every eight hours for 5 days and Chlorhexidine (Hexitol 125mg/100ml, concentration 0.125%: Arabic drug company, ADCO) antiseptic mouth wash.

Follow up phase.

a) Clinical evaluation

The two groups were evaluated, and comparison was made via a thorough follow-up after one week, two weeks and 3 months to assess postoperative pain, facial symmetry, sensory nerve function and wound healing.

Operation time(19)

The assessment of time was performed by comparing the time of the operation starting from the osteotomy to the completion of plate fixation in both groups. It was measured by minutes.

Postoperative Pain(20)

It was assessed through a 10-point Visual Analogue Scale (VAS) (20). (0-1= None, 2-4= Mild, 5-7= Moderate, 8-10= Severe)

Facial symmetry(21)

Frontal and lateral view photos of patients' face were taken for facial symmetry assessment which were compared with the preoperative photos. Facial asymmetry was noticed when the canting and difference were more than 3° and 3 mm, respectively.

Sensory nerve function(22)

Objective assessment by using Clinical Neurosensory Testing (NST) was performed by pin tactile discrimination .It was done by using the tip of pin pressing on the lower lip which is a 5-point scale. (1=no sensation, 2 =almost no sensation, 3 =some sensation, 4 = almost normal sensation, 5 = completely normal sensation.)

Wound healing(23)

The sutured wounds were examined for signs and symptoms of infection including swelling, redness, hotness, pus discharge and pain, in addition to observation for any manifestations of wound healing disturbance, as wound dehiscence, and hardware exposure at one week, two weeks and 3 months postoperatively.

b) Radiographic evaluation

Postoperative CT was obtained at 1 month postoperatively for comparison with the expected

position of the mandible in the preoperative virtual plan using Mimics innovation suite software (Figure 6).

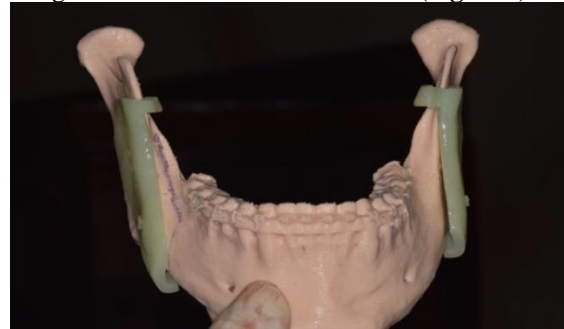


Figure 1: Showing CAD CAM osteotomy guide on a 3D printed model.

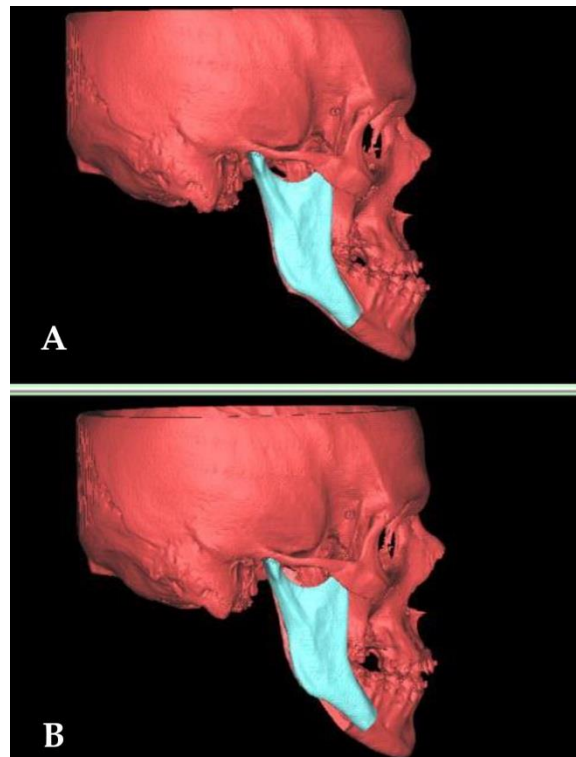


Figure 2: Showing preoperative virtual planning on proplan software.

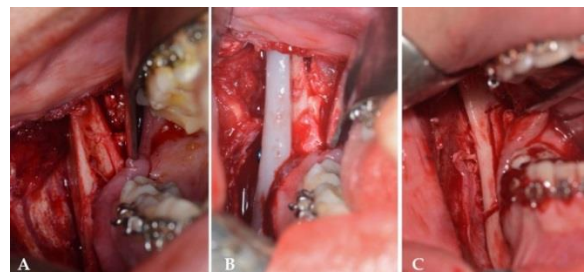


Figure 3: A) flap elevation and bone exposure. B) CAD CAM osteotomy guide placed and fixed using titanium scre. C: Osteotomy lines after removing the guide.

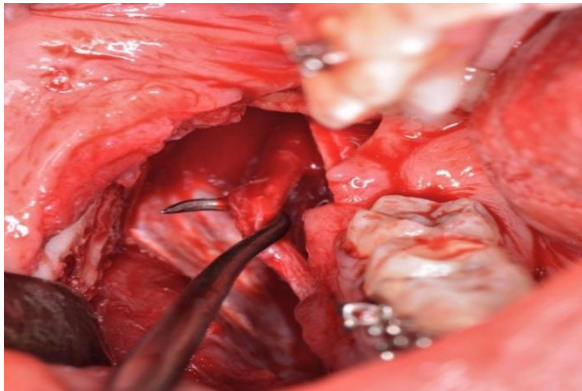


Figure 4: Showing intact IAN after BSSO.

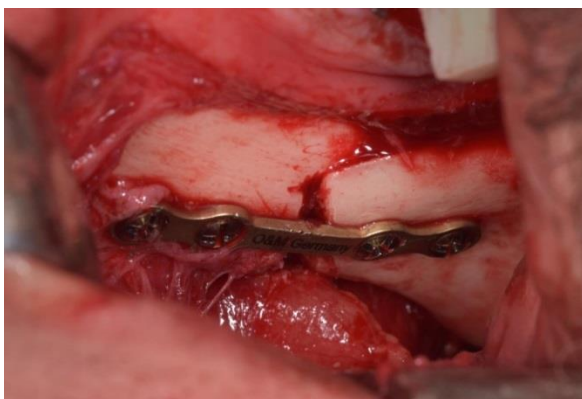


Figure 5: Showing fixation using titanium miniplates and screws.

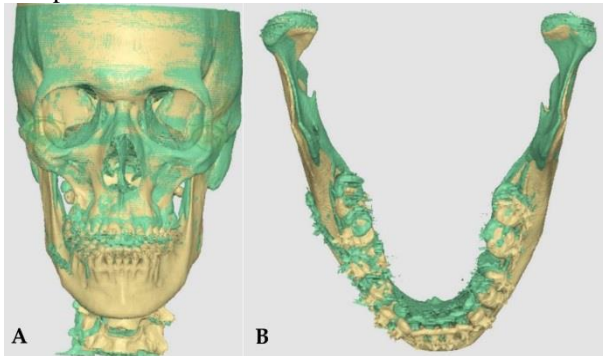


Figure 6: A & B showing postoperative CT and preoperative virtual planning superimposition.

Statistical analysis

Data were analyzed by an independent statistician using IBM SPSS software package version 20.0 (Armonk, NY: IBM Corp). Qualitative data were described using numbers and percentages. The Shapiro-Wilk test was used to verify the normality of distribution. Quantitative data were described using range (minimum and maximum), mean, standard deviation, median and interquartile range (IQR). The significance of the obtained results was judged at the 5% level. The used tests were Chi-square tests for categorical variables, to compare between different groups. Fisher’s Exact or Monte Carlo correction for chi-square when more than 20% of the cells have expected count less than 5. Paired t-test for normally

distributed quantitative variables, to compare between two periods. The student t-test for normally distributed quantitative variables, to compare between two studied groups. ANOVA with repeated measures for normally distributed quantitative variables, to compare between more than two periods or stages and Post Hoc Test (adjusted Bonferroni) for pairwise comparisons.

RESULTS

This research was conducted on a total of twenty patients of age ranging from 20 to 40 years and a mean age of 21 years. The study group consisted of five males and five females whereas the control group consisted of three males and seven females. All surgical operations were performed with no complications. Regarding the indication to the surgery, the percentage of Class III in the whole study is 80%.

Operation time

The operation time of the study group showed a statistically significant shorter than the control group ($p \leq 0.05$) (Table. 1)

Postoperative pain

The study group showed a lower mean value concerning VAS at one week, two weeks and 3 months postoperative than the control group. The results were statistically significant at one week, two weeks postoperative ($p \leq 0.05$) (Table. 2)

Facial symmetry

There was no statistically significant difference between both groups regarding facial symmetry.

Sensory nerve function

The study group showed a higher mean value concerning SNF at one week, two weeks and 3 months postoperative than the control group. The results were statistically significant at one week, two weeks postoperative ($p \leq 0.05$) (Table 3).

Table 1: Comparison between the two studied groups according to time operation.

Time operation (min.)	Control group (n = 10)	Study group (n = 10)	t	p
Min. – Max.	92.0 – 99.0	65.0 – 70.0	28.789*	<0.001*
Mean ± SD.	96.50 ± 2.46	67.0 ± 2.11		
Median (IQR)	97.50(95.0 – 98.0)	66.50(65.0 – 69.0)		

Table 2: Comparison between the two studied groups according to VAS pain.

VAS pain	Control group (n = 10)	Study group (n = 10)	t	p
2Days postoperative				
Min. – Max.	6.0 – 8.0	5.0 – 7.0	2.739*	0.013*
Mean ± SD.	7.0 ± 0.82	6.0 ± 0.82		
Median (IQR)	7.0(6.0 – 8.0)	6.0(5.0 – 7.0)		
7Days postoperative				
Min. – Max.	2.0 – 4.0	1.0 – 3.0	2.449*	0.025*
Mean ± SD.	2.80 ± 0.79	2.0 ± 0.67		
Median (IQR)	3.0(2.0 – 3.0)	2.0(2.0 – 2.0)		
Pi	<0.001*	<0.001*		

Table 3: Comparison between the two studied groups according to clinical neurosensory.

Clinical neurosensory	Control group (n = 10)	Study group (n = 10)	t	P
1Day postoperative				
Min. – Max.	1.0 – 3.0	1.0 – 3.0		
Mean ± SD.	1.80 ± 0.79	1.80 ± 0.79	0.00	1.000
Median (IQR)	2.0(1.0 – 2.0)	2.0(1.0 – 2.0)		
1week postoperative				
Min. – Max.	2.0 – 4.0	2.0 – 4.0		
Mean ± SD.	3.0 ± 0.82	3.30 ± 0.82	0.818	0.424
Median (IQR)	3.0(2.0 – 4.0)	3.50(3.0 – 4.0)		
2weeks postoperative				
Min. – Max.	3.0 – 5.0	4.0 – 5.0		
Mean ± SD.	3.70 ± 0.82	4.50 ± 0.53	2.588	0.019*
Median (IQR)	3.50(3.0 – 4.0)	4.50(4.0 – 5.0)		

Wound healing

At 2 weeks postoperatively, there was a statistically significant difference in mean wound healing of soft tissue in the two groups ($p=0.018^*$). The study group showed better soft tissue healing than the control group.

DISCUSSION

This study aimed to evaluate the efficiency of guided osteotomy in orthognathic surgery and the results showed that CAD/CAM osteotomy guide for BSSO is superior to non-guided BSSO regarding the operation time and sensory nerve involvement.

The development of computer-aided surgical simulation represents a marked shift in surgical planning for patients with craniomaxillofacial (CMF) deformities (24). Virtual surgical planning (VSP) allowed more precise analysis of the anatomical discrepancies in a three-dimensional aspect. It also granted proper visualization of the bony anatomy and studying the effect of occlusal changes on the related skeletal structures. In addition, several surgical plans could be mocked up and their impact on either hard or soft tissues would be anticipated (25, 26).

Laura (2013)(27) recommended that the traditional technique of BSSO leads to quite a few complications including injury to the inferior alveolar artery or masseteric artery which causes dramatic bleeding, unpredicted fractures and bad splits, avascular necrosis, condylar resorption, malposition of the proximal segment, and worsening of temporomandibular joint (TMJ) symptoms. Accordingly in our study we decided to compare between the conventional method and the guided osteotomy.

In our study, piezotome was used for osteotomies due to its meticulous advantages which include, reduced nerve affection, enhanced visibility of surgical field and accurate bone cutting. This runs in

parallel with Harshitha Raj (2022) (28). It provides smooth cutting due to its cavitation effect.

In our study, most of the patients were females (55%). In addition, most of the patients aged between 20.60 ± 1.71 years old. These results were coincident with other studies reported in the literature. Younger females usually are more concerned with their facial esthetics. Additionally, older population is usually aware of surgical risks and complications therefore they are not motivated to surgical management of their deformities (29-33). Majority of the patients participated in this study (80%) had Class III skeletal deformity and the other twenty percent were Class II skeletal patients. This follows with other studies which showed the same dominance of skeletal Class III patients who look for surgical intervention to correct their skeletal deformities. Patients with Class II deformities usually prefer compensatory orthodontic treatment. On the contrary, patients with Class III deformity most commonly are treated surgically. This is because the convex profile is more accepted in several cultures than the concave profile (33, 34) correspondingly, a protruding and large mandible is regarded very unaesthetic (35).

Regarding the operation time, our study showed a statistically significant decrease in the study group compared to the control group. This coincides with Schneider et al (2019)(36) who compared conventional method and virtual planning in 21 patients and noticed shorter time in the study group. It also coincides with Sun et al (2020) (37) who showed that CAD CAM guide markedly reduce the time for landmark identification and cutting lines recognition.

In addition, pain at 7 days postoperatively was statistically less for the study group than the control group. This result was predicted as in the study group, less soft tissue dissection was encountered, which means less trauma and thus inflammation.

Concerning the facial symmetry, there was no statistically significant difference between both groups. This is because, both groups were virtually planned preoperatively. This runs in agreement with the systematic review done by Zhixing Chen et al (2020)(38). Furthermore, Lin and co-workers concluded that virtual orthognathic planning yields aesthetically favorable results, a high level of patient satisfaction, accurate translation of the treatment plan and thus making the operation itself easier and safer (39).

By analyzing our results, the study group showed better responses to sensory function tests than the control group. This coincide with Al Ahmed H (40) who conducted a clinical trial of computer-assisted vs conventional BSSO (assigned in a split-mouth design) in eight patients and the results showed that

computer-assisted osteotomy is associated with better levels of neurosensory function after surgery. Regarding the wound healing, the study group showed an improved statistically significant difference than the control group. This agrees with Savoldelli et al. (41) who reported that the use of a personalized titanium device to assist bilateral sagittal split osteotomy (BSSO) allowed more accurate and less invasive drilling procedure. They considered that this guide is a promising new tool to assist BSSO. It helped to limit the extent of tissue detachment required and provided the strength necessary for accurate bone cutting and drilling. There were few drawbacks of using CAD/CAM guide for performing BSSO. This involves; increased cost and a highly experienced clinician is required to perform the virtual planning on a dedicated software. Within the limitations of this study, it can be considered that CAD/CAM osteotomy guide for BSSO is superior to non-guided BSSO in terms of the shorter operation time and better sensory nerve function. We recommend that further studies are required with a larger sample size and longer follow-up.

CONCLUSION

Within limitations, this study concludes that CAD/CAM osteotomy guide for BSSO is superior to non-guided BSSO in operation time and sensory nerve involvement.

CONFLICT OF INTEREST

The authors declare that they have no conflicts of interest.

FUNDING STATEMENT

The authors received no specific funding for this work.

REFERENCES

- Breeland G, Aktar A, Patel BC. Anatomy, Head and Neck, Mandible. StatPearls. Treasure Island (FL): StatPearls Publishing Copyright © 2023, StatPearls Publishing LLC.; 2023.
- Murphy C, Kearns G, Sleeman D, Cronin M, Allen PF. The clinical relevance of orthognathic surgery on quality of life. *Int J Oral Maxillofac Surg.* 2011;40:926-30.
- Sheikh Z, Sima C, Glogauer M. Bone replacement materials and techniques used for achieving vertical alveolar bone augmentation. *Materials.* 2015;8:2953-93.
- Simion M, Jovanovic SA, Tinti C, Benfenati SP. Long-term evaluation of osseointegrated implants inserted at the time or after vertical ridge augmentation. A retrospective study on 123 implants with 1-5 year follow-up. *Clin Oral Implants Res.* 2001;12:35-45.
- Liu J, Kerns DG. Mechanisms of guided bone regeneration: a review. *Open Dent J.* 2014;8:56-65.
- Adolphs N, Sproll C, Raguse JD, Nelson K, Heberer S, Scheifele C, et al. Stable vertical distraction osteogenesis of highly atrophic mandibles after ablative tumour surgery of the oral cavity--a salvage pathway for mandibular reconstruction prior to oral rehabilitation with dental implants. *J Craniomaxillofac Surg.* 2009;37:320-6.
- Hwang SJ, Jung JG, Jung JU, Kyung SH. Vertical alveolar bone distraction at molar region using lag screw principle. *J Oral Maxillofac Surg.* 2004;62:787-94.
- van Strijen PJ, Breuning KH, Becking AG, Perdijk FB, Tuinzing DB. Complications in bilateral mandibular distraction osteogenesis using internal devices. *Oral Surg Oral Med Oral Pathol Oral Radiol Endod.* 2003;96:392-7.
- Rauch F, Lauzier D, Travers R, Glorieux F, Hamdy R. Effects of locally applied transforming growth factor-beta1 on distraction osteogenesis in a rabbit limb-lengthening model. *Bone.* 2000;26:619-24.
- Robiony M, Toro C, Stucki-McCormick SU, Zerman N, Costa F, Politi M. The "FAD" (Floating Alveolar Device): a bidirectional distraction system for distraction osteogenesis of the alveolar process. *J Oral Maxillofac Surg.* 2004;62:136-42.
- Ghafournia M, Hajenourozali Tehrani M. Relationship between Bruxism and Malocclusion among Preschool Children in Isfahan. *J Dent Res Dent Clin Dent Prospects.* 2012;6:138-42.
- Greene JC, Vermillion JR. The Simplified Oral Hygiene Index. *J Am Dent Assoc.* 1964;68:7-13.
- De Cassai A, Boscolo A, Tonetti T, Ban I, Ori C. Assignment of ASA-physical status relates to anesthesiologists' experience: a survey-based national-study. *Korean J Anesthesiol.* 2019;72:53-9.
- Ritto FG, Schmitt ARM, Pimentel T, Canellas JV, Medeiros PJ. Comparison of the accuracy of maxillary position between conventional model surgery and virtual surgical planning. *Int J Oral Maxillofac Surg.* 2018;47:160-6.
- Abou Eleneen H, Kotb AR, Bateman CV, Aly TM, Sweedan OA. Evaluation of the use of bone-borne cad/cam surgical guides in orthognathic surgery cases requiring LE fort I osteotomy. *Alex Dent J.* 2021;46:1-7.
- Moher D. CONSORT: an evolving tool to help improve the quality of reports of randomized controlled trials. *Consolidated Standards of Reporting Trials. Jama.* 1998;279:1489-91.
- Sassouni V. A classification of skeletal facial types. *Am J Orthod.* 1969;55:109-23.

18. Bergamaschi IP, Cavalcante RC, Fanderuff M, Gerber JT, Petinati MFP, Sebastiani AM, et al. Orthognathic surgery in class II patients: a longitudinal study on quality of life, TMD, and psychological aspects. *Clin Oral Investig*. 2021;25:3801-8.
19. Bowe CM, Gurney B, Sloane J, Johnson P, Newlands C. Operative time, length of stay and reoperation rates for orthognathic surgery. *Br J Oral Maxillofac Surg*. 2021;59:163-7.
20. Seymour RA, Simpson JM, Charlton EJ, Phillips ME. An evaluation of length and end-phrase of visual analogue scales in dental pain. *Pain*. 1985;21:177-85.
21. Choi KY. Analysis of Facial Asymmetry. *Arch Craniofac Surg*. 2015;16:1-10.
22. Zuniga JR, Meyer RA, Gregg JM, Miloro M, Davis LF. The accuracy of clinical neurosensory testing for nerve injury diagnosis. *J Oral Maxillofac Surg*. 1998;56:2-8.
23. Hamzani Y, Chaushu G. Evaluation of early wound healing scales/indexes in oral surgery: A literature review. *Clin Implant Dent Relat Res*. 2018;20:1030-5.
24. Gander T, Bredell M, Eliades T, Rücker M, Essig H. Splintless orthognathic surgery: a novel technique using patient-specific implants (PSI). *J Craniomaxillofac Surg*. 2015;43:319-22.
25. Lin HH, Chang HW, Lo LJ. Development of customized positioning guides using computer-aided design and manufacturing technology for orthognathic surgery. *Int J Comput Assist Radiol Surg*. 2015;10:2021-33.
26. Xia JJ, Gateno J, Teichgraeber JF. New clinical protocol to evaluate craniomaxillofacial deformity and plan surgical correction. *J Oral Maxillofac Surg*. 2009;67:2093-106.
27. Monson LA. Bilateral sagittal split osteotomy. *Semin Plast Surg*. 2013;27:145-8.
28. Raj H, Singh M, Shah AK. Piezo-osteotomy in orthognathic surgery: A comparative clinical study. *Natl J Maxillofac Surg*. 2022;13:276-82.
29. Chew MT. Spectrum and management of dentofacial deformities in a multiethnic Asian population. *Angle Orthod*. 2006;76:806-9.
30. Ong MA. Spectrum of dentofacial deformities: a retrospective survey. *Ann Acad Med Singap*. 2004;33:239-42.
31. Marques CG, Maniglia JV, Molina FD. Service profile of Orthognathic Surgery of a medical school. *Braz J Otorhinolaryngol*. 2010;76:600-4.
32. Castro V, do Prado CJ, Neto AI, Zanetta-Barbosa D. Assessment of the epidemiological profile of patients with dentofacial deformities who underwent orthognathic surgery. *J Craniofac Surg*. 2013;24:e271-5.
33. Sato FR, Mannarino FS, Asprino L, de Moraes M. Prevalence and treatment of dentofacial deformities on a multiethnic population: a retrospective study. *Oral Maxillofac Surg*. 2014;18:173-9.
34. Phillips C, Broder HL, Bennett ME. Dentofacial disharmony: motivations for seeking treatment. *Int J Adult Orthodon Orthognath Surg*. 1997;12:7-15.
35. Suojanen J, Leikola J, Stoor P. The use of patient-specific implants in orthognathic surgery: A series of 32 maxillary osteotomy patients. *J Craniomaxillofac Surg*. 2016;44:1913-6.
36. Schneider D, Kämmerer PW, Hennig M, Schön G, Thiem DGE, Bschorer R. Customized virtual surgical planning in bimaxillary orthognathic surgery: a prospective randomized trial. *Clin Oral Investig*. 2019;23:3115-22.
37. Sun Y, Luebbbers HT, Agbaje JO, Schepers S, Vrielinck L, Lambrichts I, et al. Accuracy of upper jaw positioning with intermediate splint fabrication after virtual planning in bimaxillary orthognathic surgery. *J Craniofac Surg*. 2013;24:1871-6.
38. Chen Z, Mo S, Fan X, You Y, Ye G, Zhou N. A Meta-analysis and Systematic Review Comparing the Effectiveness of Traditional and Virtual Surgical Planning for Orthognathic Surgery: Based on Randomized Clinical Trials. *J Oral Maxillofac Surg*. 2021;79:471.e1-e19.
39. Ho CT, Lin HH, Liou EJ, Lo LJ. Three-dimensional surgical simulation improves the planning for correction of facial prognathism and asymmetry: A qualitative and quantitative study. *Sci Rep*. 2017;7:40423.
40. Al-Ahmad HT, M Saleh MW, Hussein AuM. Evaluation of an innovative computer-assisted sagittal split ramus osteotomy to reduce neurosensory alterations following orthognathic surgery: a pilot study. *Int J Med Robot Comput Assist Surg*. 2013;9:134-41.
41. Savoldelli C, Vandersteen C, Dassonville O, Santini J. Dental occlusal-surface-supported titanium guide to assist cutting and drilling in mandibular bilateral sagittal split osteotomy. *J Stomatol Oral Maxillofac Surg*. 2018;119:75-8.