

# EVALUATION OF THE USE OF MAGNETIC MALLET FOR DELAYED IMPLANT PLACEMENT IN POSTERIOR MANDIBLE (RANDOMIZED CONTROLLED CLINICAL TRIAL)

M. moataz fawzi<sup>1\*</sup> BDS, M. Prof. Dr. Saeeda Osman<sup>2</sup> PhD, M. Prof. Dr. Mohamed Shokry<sup>3</sup> PhD

## ABSTRACT

**BACKGROUND:** Instead of using drills for implant bone site preparation, new tools have been developed to decrease surgical stress, gain more control over the incision, boost primary stability, and shorten recovery and morbidity periods. A novel apparatus that utilises magneto-dynamic technology has been suggested for use in bone surgical procedures, such as the preparation of dental implant sites.

**AIM OF THE STUDY:** Evaluation of the use of magnetic mallet versus conventional drill system for delayed implant placement in posterior mandible.

**MATERIALS AND METHODS:** A randomized, controlled, clinical trial was carried out in patients requiring dental implants to replace their extracted tooth in posterior mandible. Patients who met the inclusion criteria was randomly divided in to two groups: study group (osteotomy with magnetic mallet) and controlled group (osteotomy with conventional drill system) and this was clinically evaluated (primary and secondary stability evaluation ) and radiographically evaluated (bone density evaluation).

**RESULTS:** Implants done with magnetic mallet had a statistically significant higher primary stability than Implants done with drill system and Secondary stability was statistically significant higher in study group than Implants done in control group while Both methods are comparable regarding the bone density.

**CONCLUSION:** Magnetic mallet show better significant primary stability, and secondary stability than the conventional drill system. Both methods are comparable regarding the bone density.

**RUNNING TITLE:** Evaluation of the use of magnetic mallet versus conventional drill system for delayed implant placement in posterior mandible.

**KEYWORDS:** dental Implant, conventional implant drilling, magnetic mallet, primary stability, posterior mandible

---

1-BDS, 2012, Faculty of Dentistry, Alexandria University, Egypt.

2-Professor of Oral and Maxillofacial Surgery, Department of Oral and Maxillofacial Surgery Faculty of Dentistry, Alexandria University, Egypt.

3-Professor of Oral and Maxillofacial Surgery, Department of Oral and Maxillofacial Surgery Faculty of Dentistry, Alexandria University, Egypt.

**\*Corresponding author:**

[moataz.abdulaziz2017@gmail.com](mailto:moataz.abdulaziz2017@gmail.com)

## INTRODUCTION

Preparing the implant location is a technique-sensitive process. A good osseointegration can be anticipated if the procedure is carried out non-traumatically and appropriately. Conventional implant shaping drills are commonly utilised due to their affordability, ease of usage, and efficiency in terms of time (1).

Yet, the heat they produce could result in tissue damage, necrosis to the surrounding structures, trouble arranging the objects in three dimensions, and even the possibility of them invading and harming vital anatomical structures like the Schneiderian membrane and the inferior alveolar nerve (2).

Osseodensification has been observed to produce more bone-to-implant contact, enhanced primary and secondary stability, and higher bone volume surrounding implants as compared to

standard drilling. This advantageous result is made possible by the drills' many lands with significant negative rake angles, which function as noncutting edges to enlarge the implant site and raise the bone's density (6).

The transition from primary mechanical stability to secondary biological stability occurs after implant installation and during the osseous healing period. This physiological drop in implant stability is caused by the resorption of the bone tissue immediately lateral to the implant, which occurs during the first 1-4 weeks of the healing period (7).

By utilising the laws of electromagnetic, magneto-dynamic technology applies controlled forces to a body in the shortest amount of time. Both patients and doctors can feel secure during the treatments because of the steady and controlled application of pressures. In 1873, William Bonwill

received a patent for the first electric dental mallet, which was used to fill cavities with gold (6).

The Magnetic Mallet (MM) gadget uses magneto-dynamic technology in dentistry procedures in the twenty-first century. The MM consists of a handpiece that is powered by a power control mechanism and applies forces based on time. Depending on the surgical technique, several inserts might be fastened to the handpiece, which applies a shock wave to its tip (7).

Therefore this study was conducted to evaluate the use of magnetic mallet versus traditional drill for delayed implant placement in posterior mandible radiographically, bone density evaluated using CBCT (by blue sky bio software) and to evaluate clinically primary stability by using ostell ISQ at implant placement and after 4 months at abutment placement.

The Null hypothesis is there will be no statistically significant difference between the use of magnetic mallet versus conventional drill system in delayed implant placement in posterior mandible in terms of primary stability and bone density.

## MATERIAL AND METHOD

### MATERIAL

magnetic mallet (Italian company [www.osseotouch.com](http://www.osseotouch.com))

Surgical kit of magnetic mallet (Italian company [www.osseotouch.com](http://www.osseotouch.com))

biodem implant (German company ([www.bio-dem.com](http://www.bio-dem.com)))

Implant motor (German company ([www.bio-dem.com](http://www.bio-dem.com)))

Surgical kit of implant system (German company ([www.bio-dem.com](http://www.bio-dem.com)))

ostell ISQ (U.S.A. company [www.osstell.com](http://www.osstell.com))

### Study design

This study was a randomized controlled trial with two groups (study group and control group) with 1:1 allocation ratio. The study was reported according to the CONSORT guidelines([www.consort-statement.org](http://www.consort-statement.org)).

### Study setting and location

fourteen Patients were recruited from the Outpatient Clinics of Oral and Maxillofacial Surgery Department, Faculty of Dentistry, Alexandria University, Egypt. The surgical procedure were performed at the minor oral surgery clinic of the same place.

### Sample size estimation

Sample size was estimated assuming 5% alpha error and 80% study power. According to Crespi et al, (9) the mean (SD) marginal bone loss after 4 months was 0.94 (0.31) mm for the magnetic mallet group. The conventional drilling group had a mean marginal bone loss of 0.17 (0.65) mm. (8) Based on difference between two independent means using pooled SD=0.48 mm, the minimum sample size was calculated to be 7 patients per group. Total

sample= number per group x number of groups= 7 x 2 = 14 patients

### Software

Sample size was based on Rosner's method (10) calculated by Brant's sample size calculator at the University of British Columbia. (11)

### Sample randomization

Eligible patients were allocated randomly into two equal groups with seven patients in each according to the surgical technique operated to them by simple randomization using computer generated random numbers, study group consists of seven patients, in whom delayed implant were placed with magnetic mallet in posterior mandible, control group consists of seven patients, in whom delayed implant were placed with conventional drill system in posterior mandible.

### Allocation concealment

An assistant were responsible for giving each patient a serial number that was used for its allocation A duplicate of this number were kept in an opaque envelope indicating to which group the patient belongs. This envelope was kept by a trial independent individual who were assigned the role of opening it only at the time of intervention; so that the group to which the patient is allocated was concealed from the investigator.

### Eligibility criteria

The criteria for including patients were as follows:

Inclusion criteria: Patients with previously extracted at least 6 months ago tooth in posterior mandible, patient with adequate ridge height (10-14) and width(5-8). Age between 25 - 50 years old, with good oral hygiene and Adequate inter-occlusal distance and D2 or D3 bone quality

Exclusion criteria: Parafunctional habits (Bruxism or clenching), patients with systemic conditions contraindicating surgery, Patients receiving chemotherapy or radiotherapy and Immunosuppressed patients (for example: following organ transplantation).

### I- Preoperative phase

Medical History of the patient: was recorded in full details including name, age, gender, occupation, address and general medical health then, Clinical examination evaluated the site of implant placement, inter-occlusal distance, the status of neighboring teeth and soft tissue and patient signed informed consent.

After that, Pre-operative radiographic examination using segmented cone beam computed tomography (CBCT) were performed for all patients for the purpose of diagnosis and treatment planning, and selection of proper size of dental implant and last phase Pre-operative preparation scaling and root planning for all patients and oral hygiene instruction and Fabrication of computerized surgical guide for all patients.

### II- Surgical Phase

All surgical procedures were performed under aseptic conditions, all patients were received infiltration local anesthesia (Articaine 4% 1:100 000 epinephrine (Alexadircaine (1:100000))) Flap design A midcrestal incision and gingival incision were made using No. 15 blade where buccal mucoperiosteal flaps reflected and reflection of lingual side one tooth before implant site and one tooth after implant site in a full thickness approach exposing the crestal part of alveolar ridge. The implant site were marked with a 2.0 mm pilot drill guided by the surgical guide which previously permormed throught cast scan.<sup>(13)</sup> Osteotomy for study group had done with the sequence of drilling by (magnetic mallet) osteotomy kit we use pilot drill (MM-f-100D) which had apex diammter of 1 mm and 4 mm at base with full length of 15 mm then drill (MM-F-200D) which had apex 2mm diameter and 4.3 mm at base with full length of 16.1 mm we stop at mark of 10 mm which suitable for implant length, device have four powers we use power number 2, and for control group had done with the sequence of drilling by osteotomy kit of conventional drill system with torque 40 and speed 700 we first use pilot drill and then first drill of diameter 3mm and length 10 mm. For both groups Implant placement manually by torque ranch all implants for both groups were biodem implant then we used osstell ISQ osstell device was used to measure the implant stability via implant stability quotient (ISQ) value immediately after surgery, then cover screw were inserted. Suture closure interrupted suture by 3/0 silk suture. (21) Fig. 1:(A-I)

### III. Post-operative phase

Post-operative instructions: cold fomentation for the first 24 hours, warm mouthwash starting from the next day, and oral hygiene recommendations.

Post-operative medication: antibiotic in the form of Amoxicillin 875mg + Clavulanic acid 125mg tablets for 7 days 2 times daily (Augmentin 1 g tablet: Amoxicillin 875 mg + Clavulanic acid 125 mg: Glaxo SmithKline, UK.), non-steroidal anti-inflammatory drug Diclofenac potassium 50 mg tablets for 5 days 3 times daily (Cataflam 50 mg Novartis Switzerland), and warm mouth wash chlorohexidine HCL (0.12%) from the second day (Hexitol, Arab Drug Company ,Egypt).

### Post-operative follow up

Clinical evaluation Primary stability by using Ostell ISQ at implant placement and after 4 months at abutment placement.

Post-operative radiographic evaluation (14, 15) Cone Beam CT (CBCT) were used after 4 months to evaluate Bone density.

Radiographically, CBCTs were used to measure the bone density before and after implant placement. Cross sectional cuts were taken and the implant length was determined, then a line was drawn in the middle and perpendicular to the

implant. Another two lines buccal and lingual to the implant were drawn each of five mm length at the end of each line we draw a square of 13 unit each side and measure reading in each square, the mean of the two readings were recorded to give the mean bone density around the implants. Fig.2: (A, B)

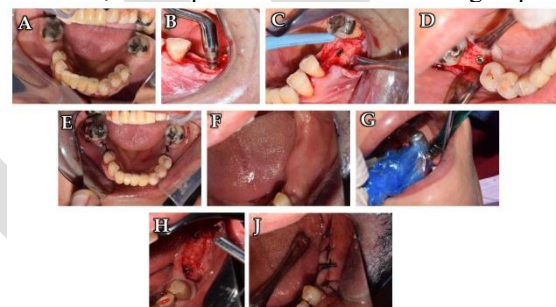
### IV- Prosthetic phase

The final restorations were loaded after 4 months postoperatively. Fig.3:(A, B)

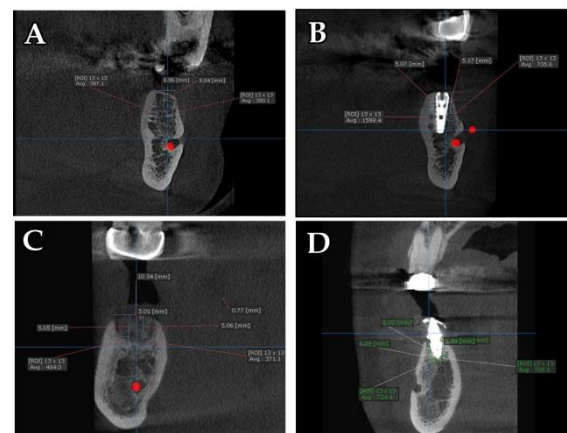
### Statistical analysis of the data

Data were fed to the computer and analyzed using IBM SPSS software package version 20.0. (Armonk, NY: IBM Corp) Qualitative data were described using number and percent. The Shapiro-Wilk test was used to verify the normality of distribution Quantitative data were described using range (minimum and maximum), mean, standard deviation, median. Significance of the obtained results was judged at the 5% level.

The used tests were Student t-test for normally distributed quantitative variables, to compare between two studied groups, Paired t-test For normally distributed quantitative variables, to compare between two periods and Mann Whitney test For abnormally distributed quantitative variables, to compare between two studied groups

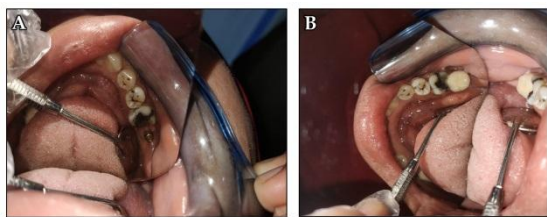


**Figure 1:** (A) Ostell ISQ. (B) Magnetic mallet. (C) Osteotome kit of magnetic mallet. (D) Midcrestal incision study group. (E) suture closure study group.



**Figure 2:** (A) Preoperative bone density. (B) Bone density measurement 4 months postoperative.





**Figure 3:** (A) Abutment installation (study group). (B) Crown installation (study group).

## RESULTS

This study was conducted on fourteen patients who required dental implant at lower posterior teeth seven patients will undergo treatment by magnetic mallet for delayed implant placement in posterior mandible and seven patients will undergo treatment by conventional drill system for delayed implant placement in posterior mandible.

Eight were female presenting 57% of cases, and six were male presenting 43% of cases. The age mean is 35-50 years.

In the current trial, we assessed both the primary and secondary stability of the magnetic mallet and conventional drill system.

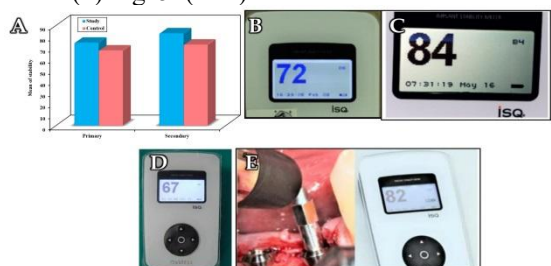
Implants done with magnetic mallet had a statistically significant higher primary stability ( $74.43 \pm 4.28$ ) than Implants done with drill system ( $67.43 \pm 5.91$ ) with  $p$  value = 0.026.

Also, in secondary stability, it was statistically significant higher in group A ( $82.86 \pm 3.80$ ) than implants done in group B ( $72.71 \pm 9.52$ ) with  $p$  value = 0.022. Table (1) Fig. 4. (A-E)

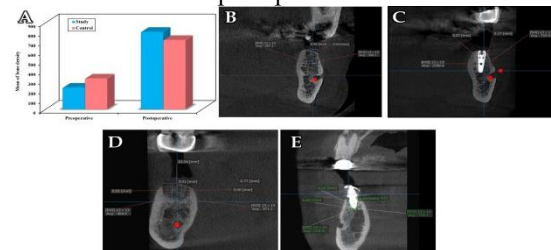
This study compared between both groups regarding the preoperative and postoperative bone density, we find that the difference of the Mean  $\pm$  SD of bone density with magnetic mallet method was statistically significant by  $224.9 \pm 118.6$  preoperatively and  $805.6 \pm 246.6$  postoperative with maximum preoperative density of 388 and postoperative density of 1150 ( $p$  value = 0.002).

On the other hand, the control group with conventional drill system show a statistically significant increase in the postoperative bone density than the preoperative density ( $721.0 \pm 127.5$  versus  $320.0 \pm 108.2$ ) with maximum preoperative density of 550 and postoperative density of 829 ( $p$  value < 0.001).

However, the difference between the study group and the control group in both preoperative and postoperative density was statistically insignificant. Table (2) Fig. 5. (A-E)



**Figure 4:** (A) Comparison between study group and control group according to stability. (B) Study group: case 1 stability measured immediately after implant placement. (C) Study group: case 1 stability measured after 4 months of implant placement. (D) Control group: stability measured immediately after implant placement. (E) Control group: stability measured after 4 months of implant placement.



**Figure 5:** (A) Comparison between study group and control group groups according to bone density. (B) Study group case 1 preoperative bone density. (C) Study group case 1 Bone density after 4 months postoperatively. (D) Control group preoperative bone density. (E) Control group Bone density after 4 months postoperatively.

**Table (1):** Comparison between the two studied groups according to stability

Stability	Study (n = 7)	Control (n = 7)	T	P
Primary				
Min.	70.0	60.0		
Max.	83.0	75.0		
Mean $\pm$ SD.	$74.43 \pm 4.28$	$67.43 \pm 5.91$	2.538*	0.026*
Median	74.0	69.0		
Secondary				
Min.	80.0	52.0		
Max.	91.0	80.0		
Mean $\pm$ SD.	$82.86 \pm 3.80$	$72.71 \pm 9.52$	2.618*	0.022*
Median	82.0	75.0		

SD: Standard deviation t: Student t-test

p: p value for comparing between the studied groups

\*: Statistically significant at  $p \leq 0.05$

**Table (2):** Comparison between the two studied groups according to bone density.

Bone density	Study (n = 7)	Control (n = 7)	t	P
Preoperative				
Min.	30.0	230.0		
Max.	388.0	550.0		
Mean $\pm$ SD.	$224.9 \pm 118.6$	$320.0 \pm 108.2$	1.568	0.143
Median	215.0	291.0		
Postoperative				
Min.	503.0	452.0		
Max.	1150.0	829.0		
Mean $\pm$ SD.	$805.6 \pm 246.6$	$721.0 \pm 127.5$	0.806	0.436
Median	823.0	750.0		
p1	0.002*	<0.001*		

**SD: Standard deviation t: Student t-test**

p: p value for comparing between the studied groups

p<sub>0</sub>: p value for **Paired t-test** for comparing between pre and post in each group

\*: Statistically significant at  $p \leq 0.05$

**DISCUSSION**

In the field of oral implantology, several novel technologies have emerged over time. The invention of "magnetic mallets" is one such example. In 1873, Bonwill became the first person in stomatology to patent the dental magnet. It was invented with the intention of improving the efficacy of fillings made of hammered gold, which would be accomplished by even and constant mildly intense mechanical pounding (12).

Moreover, the handpiece may be equipped with several interchangeable tips according to the operation being carried out. The mallet is operated using a pedal control. There are four force modifications available with the present magnetic mallets: 75, 90, 130, and 260 kp (16).

Bone density is a major factor in implantology's success, and magnetic mallets significantly altered the course of dental implant dentistry (17).

Therefore, the current trial aimed to evaluate of the use of magnetic mallet versus conventional drill system for delayed implant placement in posterior mandible with randomized, controlled, parallel-group design.

In this study, which was a randomized controlled trial with two groups (study group and control group) and a 1:1 allocation ratio, seven patients in study group received treatment using a magnetic mallet for delayed implant placement in the posterior mandible, and seven patients in control group received treatment using a conventional drill system.

Osteotomy for study group was done with the sequence of drilling by (magnetic mallet) osteotomy kit, and for control group were done with the sequence of drilling by osteotomy kit of conventional drill system. Implant placement manually by torque ranch, osstell ISQ device to measure implant stability.

In the current trial, we assessed both the primary and secondary stability of the magnetic mallet and conventional drill system.

Implants done with magnetic mallet had a statistically significant higher primary stability ( $74.43 \pm 4.28$ ) than Implants done with drill system ( $67.43 \pm 5.91$ ) with p value = 0.026.

Also, in secondary stability, it was statistically significant higher in study group ( $82.86 \pm 3.80$ ) than implants done in control group ( $72.71 \pm 9.52$ ) with p value = 0.022.

Consequently, our findings support the use of magnetic mallets. Additionally, in vitro research

by Antonelli, A. et al. 2023 showed that both implant macro-geometries show good primary stability, and ex vivo histological analyses may shed light on the magnetodynamic technique's potential for bone condensation (18).

According to histological investigations, Schierano G et al., 2021 corroborate our findings that the magnetic-dynamic mallet approach may considerably enhance the quantity of osteoblasts and newly generated bone tissue when compared to the drill technique. The main stability can be positively impacted by the mallet's inherent propensity to osteocondensate bone tissue (19).

In This study the difference between the study group and the control group in both preoperative and postoperative density was statistically insignificant.

Consequently, our findings support the use of magnetic mallets. Additionally, Schierano G et al, 2021 and Antonelli, A et al, 2023 Histological confirm this research findings that, as compared to the drill method, the magnetic-dynamic mallet approach may greatly enhance the quantity of osteoblasts and newly created bone tissue (19, 20). Additionally, Gáspár, 2019 who described the successful outcomes and the magnetic mallet surgical approach, came to the conclusion that the magnetic mallet allows implant sockets to be prepared with the least amount of bone loss in patients who are at risk or have lower bone mass (12).

In some cases there is no bone loss at all and, in a lesser rate, there is minimal bone loss, which is just a small part of that compared to the bone loss made by traditional drills (12).

The in vitro findings that Antonelli, A. et al. 2023 reported showed that bone density and the connection between the implant surface and the bone walls seem to be impacted by the surgical preparation of the implant site. In particular, independent of the fixture design, the magnetodynamic approach seems to achieve greater peak insertion torque, peak removal torque, and implant stability quotient values than the conventional method. (20).

The earlier discovery could be the result of the device's remarkably simple handling due to the ease with which the mechanical vibrations sent to the osteotome are transferred to the bone.

**Limitations**

This study was single center with small sample size and short follow-up period.

**CONCLUSION**

Magnetic mallet show better significant primary stability, and secondary stability than the conventional drill system. Both methods are comparable regarding the bone density.

**RECOMMENDATION**

Magnetic mallet is recommend for delayed implant placement in posterior mandible over the conventional drill system.

We recommend testing our hypothesis and studying design on a higher sample size in different areas and longer follow up period to assess the success rate of both methods.

#### CONFLICT OF INTEREST

The authors declared no potential conflicts of interest with respect to the research, authorship, and/or publication of this article

#### FUNDING

The authors received no financial support for the research, authorship, and/or publication of this article.

## REFERENCES

- Sendyk DI, de Oliveira NK, Pannuti CM, da Graça Naclério-Homem M, Wennerberg A, Deboni MCZ. Conventional Drilling Versus Piezosurgery for Implant Site Preparation: A Meta-Analysis. *J Oral Implantol*. 2018;44:400-5.
- Chiriac G, Herten M, Schwarz F, Rothamel D, Becker J. Autogenous bone chips: influence of a new piezoelectric device (Piezosurgery) on chip morphology, cell viability and differentiation. *J Clin Periodontol*. 2005;32:994-9.
- Rashad A, Kaiser A, Prochnow N, Schmitz I, Hoffmann E, Maurer P. Heat production during different ultrasonic and conventional osteotomy preparations for dental implants. *Clin Oral Implants Res*. 2011;22:1361-5.
- Sirilli M, Mafra CE, Santos RA, Saraiva L, Holzhausen M, César JBN. Influence of Piezosurgery on Bone Healing around Titanium Implants: A Histological Study in Rats. *Braz Dent J*. 2016;27:278-83.
- Scheven BA, Shelton RM, Cooper PR, Walmsley AD, Smith AJ. Therapeutic ultrasound for dental tissue repair. *Med Hypotheses*. 2009;73:591-3.
- Vercellotti T, Nevins ML, Kim DM, Nevins M, Wada K, Schenk RK, et al. Osseous response following resective therapy with piezosurgery. *Int J Periodontics Restorative Dent*. 2005;25:543-9.
- Preti G, Martinasso G, Peirone B, Navone R, Manzella C, Muzio G, et al. Cytokines and growth factors involved in the osseointegration of oral titanium implants positioned using piezoelectric bone surgery versus a drill technique: a pilot study in minipigs. *J Periodontol*. 2007;78:716-22.
- Crespi R, Cappare P, Gherlone E. A comparison of manual and electrical mallet in maxillary bone condensing for immediately loaded implants: A randomized study. *Clin Implant Dent Relat Res*. 2014;16(3):374-82.
- Knight WM. Comparison of Marginal Bone Loss in Conventional Versus Osseodensification Implant Site Preparation: A Retrospective Study. Master's thesis, Texas A&M University. 2021. Available electronically from <https://hdl.handle.net/1969.1/195818>.
- Rosner B. Hypothesis Testing: Two-Sample Inference. In: *Fundamentals of biostatistics*. 7th ed. Boston: Brooks/Cole. Nelson Education. 2015;269-301.
- Sample size calculator available at <https://www.stat.ubc.ca/~rollin/stats/ssize/n2.html>. Accessed April 5, 2022.
- Gasper L. Use of the magnetic mallet in bone-shaping and implantology. 2019;4:16-30.
- Miloro M, Ghali GE, Larsen PE, Waite P. Peterson's Principles of Oral and Maxillofacial Surgery. 4th ed. Germany: Springer; 2022.
- Cassetta M, Stefanelli LV, Di Carlo S, Pompa G, Barbato E. The accuracy of CBCT in measuring jaws bone density. *Eur Rev Med Pharmacol Sci*. 2012;16:1425-9.
- Ibraheem EMA, Hammad HGH, El-Sisy AME. Comparing marginal bone height changes around immediately and delayed implant-retained mandibular overdentures in controlled diabetic patients: a randomized clinical study. *Bulletin of the National Research Centre*. 2019;43:1-8.
- Bennardo F, Barone S, Vocaturo C, Nucci L, Antonelli A, Giudice A. Usefulness of Magnetic Mallet in Oral Surgery and Implantology: A Systematic Review. *J Pers Med*. 2022;12.
- Crespi R, Cappare P, Gherlone E. Electrical mallet provides essential advantages in maxillary bone condensing. A prospective clinical study. *Clin Implant Dent Relat Res*. 2013;15:874-82.
- Visale K, Manimala V, Vidhyasankari N, Shanmugapriya S. Magnetic mallets—A stroke of luck in implantology: A review. *J Dent Educ*. 2021;7:6-9.
- Schierano G, Baldi D, Peirone B, Mauthe von Degerfeld M, Navone R, Bragoni A, et al. Biomolecular, Histological, Clinical, and Radiological Analyses of Dental Implant Bone Sites Prepared Using Magnetic Mallet Technology: A Pilot Study in Animals. *Materials (Basel)*. 2021;14.
- Antonelli A, Barone S, Attanasio F, Salviati M, Cerra MG, Calabria E, et al. Effect of Implant Macro-Design and Magnetodynamic Surgical Preparation on Primary Implant Stability: An In Vitro Investigation. *Dent J (Basel)*. 2023;11.
- Incisions and Tissue Management in Periodontal Surgery, author={Raphael Borchard and Heinz Erpenstein}, year={2004},