

EVALUATION OF THE EFFICIENCY OF ALVEOLAR DISTRACTION DEVICE IN THE TREATMENT OF POSTERIOR ATROPHIC MANDIBLE (A CLINICAL TRIAL)

Amany M. Alrayess^{1*} BDS, Adham A. El Ashwah² PhD,
Lydia N.F. Melek³ PhD, Nevien S. Abdallah² PhD, Hoda M. Abdel-
Naby⁴ PhD

ABSTRACT

BACKGROUND: Atrophic alveolar bone presents a unique difficulty, preventing correct implant placement and affecting long-term **RESULTS.** Different techniques are recommended to restore the proper length of the posterior ridge of the mandible and thus achieve proper form and function, one of those is distraction osteogenesis. Refinements in the technique can improve the treatment outcome and decrease postoperative complications.

AIM OF THIS STUDY: this study evaluated the efficiency of guided alveolar distraction devices in the treatment of the posterior atrophic mandible.

PATIENTS AND METHODS: Seven patients with atrophic posterior mandible were included in the study and treated with a guided alveolar distraction device. Patients were examined preoperative and evaluated clinically, and radiographically immediately postoperative, post-activation and 3 months post-activation to calculate the length gained and bone density at the distracted area.

RESULT: There was a statistically significant difference in the length gained between evaluation times as well as a statistically significant difference in bone density at the distracted area through the study periods.

CONCLUSION: alveolar distraction osteogenesis provides significant vertical ridge augmentation while simultaneously expanding soft tissue. It also promotes sufficient bone formation with good quality and density which allows for implant placement easily. This technique also shows a decrease in the pain intensity and displays promising wound healing results through the study periods. The use of surgical guides to guide the osteotomies and to put the distractor on the preplanned holes accurately increased the accuracy of the operation and decreased the postoperative complications.

KEYWORDS: Alveolar Distraction, guided distraction, Atrophic, Mandible.

RUNNING TITLE: Evaluation of the efficiency of alveolar distraction device

1-Assistant lecturer of Oral and Maxillofacial Surgery, Faculty of Dentistry , Alexandria University

2-Professor of Oral and Maxillofacial Surgery, Faculty of Dentistry, Alexandria University, Alexandria, Egypt

3-Associate Professor of Oral and Maxillofacial Surgery, Faculty of Dentistry, Alexandria University, Alexandria, Egypt

4-Associate Professor of Rheumatology, Rehabilitation and Physical Medicine

**Corresponding author:*

amanyalryess@gmail.com

INTRODUCTION:

In modern times, endosseous implants have become the preferred method for prosthetic restoration. However, patients who do not have sufficient alveolar bone seeking durable solutions for their dental rehabilitation (1).

Posterior teeth can be lost due to various reasons such as trauma, aggressive tumors that need marginal resection, or periodontal disease. The alveolar bone begins to resorb after extraction and the maximum resorption will be in the first year (2). When we have enough bone volume thus allow for good

interarch space and the inconsequence crown-to-root ratio will be perfect which offers an excellent prosthetic outcome. For posterior lower alveolar ridge deficiencies, several regenerative methods have been used to augment them. These methods include onlay bone grafting (3, 4), guided bone regeneration, (4, 5) sandwich osteotomy (6) vertical tent pole (7), short dental implant (8), IAN lateralization,(9) and distraction osteogenesis (DO) (10).

Augmentation methods have their pros and cons. For example, graft size in onlay bone grafting experiences a notable decrease due to factors such as

resorption caused by postoperative infection, exposure to the oral cavity, or inadequate blood supply. Donor site complications have also been recorded (3). Guided bone regeneration is widely used in the correction of minor deficiencies, it is known for its limitation in creating extra length bone (5).

Certainly, to allow for accurate placement of dental implants, you must be sure of appropriate bone dimensions at the desired implant site. The presence of 7 mm residual alveolar bone height and width of 6 mm at least to allow the good stability of short implant (11). Inferior alveolar nerve lateralization has the major advantage of needing one surgical intervention, which omits the idea of donor-site morbidity. However, this surgical procedure has a great potential to damage the inferior alveolar nerve. Also, mandibular fractures can occur (12). Another disadvantage of this method is the incorrect ratio between the crown to the implant due to the lack of vertical augmentation (11).

The expected good results with hard and soft tissue together are not obtained in many of the techniques used for alveolar bone augmentation. For that, the applications of distraction osteogenesis (DO) have gradually increased in the last two decades (13, 14).

When it comes to bone formation using DO, Ilizarov talked about the tension stress influence on the development of bone and soft tissues and emphasized the demand for loading and good blood supply for bones. He intended to preserve the periosteum and adjacent soft tissue which plays a crucial role in minimizing complications. He also emphasized the significance of stability and control over the lengthening vector (15).

The method is unique because it elongates the soft tissue envelope and at the same time promotes bone stabilization and reconstruction. This is critical in the augmentation intraorally, where insufficient soft tissue is the primary cause of the failure in the bone graft augmentation. (14).

The primary benefit of vertical alveolar distraction osteogenesis is increased bone height while simultaneously lengthening associated soft tissues via histogenesis. This method also avoids the necessity for additional procedures like vestibuloplasty, which could be essential for other bone augmentation techniques. (16, 17).

Esposito et al (18) in their systematic review didn't find conclusive evidence regarding the optimal procedure for vertical regeneration. However, they highlighted that the alveolar distraction osteogenesis (ADO) holds significant potential in vertical lengthening.

The method also has drawbacks, including the risk of fibrous union, nonunion of the bone and with the main problem of accurate control of the

direction of distractor. Inappropriate direction of distraction caused by several factors such as: local muscle pull, inappropriate device position, inaccurate osteotomy cuts, poor device trajectory.

To prevent these problems, there is a device which is an extraosseous distractor device that can modify the vector of distraction in several planes of space vertical and in buccolingual direction and guided with many 3-D guides for better function outcomes.

According to a study, 3-D printing is gaining significant attention in the field of craniomaxillofacial surgery. The advantages of 3-D printing include enhanced preoperative planning, improved surgical accuracy, reduced operating room time, and fewer post-operative complications (19, 20).

In the field of distraction osteogenesis, piezo surgery is crucial to preserve osteocytes and periosteal tissues, which together form a biological bed for bone regeneration. This helps maintain the vascularity required that allows new bone formation. (21)(22). In his article, the alternative hypothesis is the use of guided alveolar distraction device shows better length of the bone with better bone density in the treatment of the posterior atrophic mandible.

MATERIALS AND METHODS

Study design

The study was a clinical trial that was designed and reported by modified CONSORT guidelines (23).

The PIO question was for patients presented with atrophic posterior mandible requiring ridge lengthening, does the use of a guided alveolar distraction device offer promising results, in terms of pain, wound healing, bone density, and vertical bone gained postoperatively.

Participants were recruited from the Outpatient Clinic of Alexandria University Teaching Hospital and operated in the Oral and Maxillofacial Surgery Department, Faculty of Dentistry, Alexandria University.

Patients were informed about the procedure that would be performed, and each participant signed an informed consent form. The sample was chosen to meet the required inclusion and exclusion criteria.

The sample size was estimated based on assuming a 5% alpha error and 80% study power. The mean (SD) bone density preoperatively was 796.33 (179.47) and 512.50 (99.64) postoperatively for patients treated by osteogenic alveolar distraction. (14) Based on the difference between the two dependent means using the highest SD = 179.47 to ensure enough study power, the minimum sample size was calculated to be 6 patients, increased to 7 patients to make up for lost follow-up cases.

The sample size was based on Rosner's method (24) calculated by G*Power 3.1.9.7 (25).

Inclusion criteria: All patients ages ranged from 30-60 years old who agreed to be committed to all follow-up visits for a minimum period of 4 months postoperatively and they presented with posterior atrophic mandible and the distance from the alveolar crest to the upper border of the canal not less than 6 mm. All Patients had adequate oral hygiene (26).

Exclusion criteria: Patients were excluded if they are medically compromised patients contradicting operation (ASA III, IV & V), patients receiving radiotherapy or chemotherapy or bisphosphonate, bone diseases, any habits that might retard healing such as heavy smoking or alcoholism, and history of any grafting procedure at the designated area.

Materials

Equipment will be used:

Biaxial distractor device and Titanium screws (Arabic Engineers for Designs and Medical Instrument, Cairo, Egypt, Manufactured by JEIL Medical Corporation Company: Seoul, Korea. www.jeilmed.co.kr). (Figure 1)

Piezotome system (ACTEON, Merignac, France.).

Computed tomography (CBCT) device (Ingenuity Core; Philips Medical Systems, Cleveland, OH).

Intervention

Presurgical phase

A preoperative assessment was performed which included the history, intraoral, and extraoral clinical examination.

Radio-logical evaluation using CBCT scan.

Preoperative virtual treatment planning and the design process of the 3D printed guides were done.

a- Virtual surgical planning

Planning was accomplished using specialized CBCT, DICOM format, and segmentation software (Materialise innovation suite (Mimics and 3Matic): Materialise, Leuven, Belgium, mimics@materialise.be). The created 3D models of the mandible and the inferior alveolar canal (IAC) were fed to a designing software on which a bone-cutting guide and a guide for the outline of the canal were created. The bone-cutting guide was created 2 mm away from the 3D model of the IAC. On the printed mandible, the IAC outlining guide was seated to draw the IAC on the buccal surface of the printed model. Furthermore, the cutting guide was seated on the printed mandible and a pencil was used to draw the provisional outline of the bone cuts on the printed mandible. The distractor was seated on the printed mandible and, using the outlines drawn on it, the basal holes of the distractor were ensured to be below the projection of the IAC, and the movable plate holes were ensured to be within the boundaries of the cutting guide. Drilling of the distractor holes in the printed mandible was performed. The mandible with drills boreholes were scanned using Omnicam Sirona

(Dentsply Sirona. (2017). CEREC Omnicam AC Operating Instructions Manual). The scanned mandible with the distractor holes was superimposed on the original mandible on the designing software (3Matic; Materialise). The position of the movable plate holes was subtracted from the cutting guide. The final cutting guide with the boreholes for the distractor's movable plate was printed using fused deposition modelling FDM technology. (Figure 2)

b- Preoperative Sterilization (27)

The surgical guide was sterilized following the Center for Disease Control (CDC) recommended guidelines, by soaking the finished product in fresh 70% Isopropyl Alcohol (IPA) for 5 minutes. The distractor was autoclaved in a conventional manner.

Preoperative patient preparation

Patients were done all the necessary laboratory investigations to be accepted for operation by the anesthesia specialist. They were instructed to fast at least 8 hours before the surgery.

Prophylactic antibiotic (amoxicillin and clavulanate potassium 1 gm vial) was administered preoperatively.

Operative procedure (28, 29) (Figure 3)

The surgical procedure commenced by creating a mucoperiosteal flap that extended buccally to the midcrestal area. This flap allowed the attached mucosa to remain connected to the bone on the lingual side. Subsequently, three osteotomies were performed to shape the bone into a trapezoidal crestal segment which was guided by a surgical guide to assist in the correct position of osteotomy and to mark the distractor screw sites. For the osteotomies, we used a piezosurgery device to create inverted trapezoidal shape osteotomies.

To ensure successful stabilization of the distractor device and prevent segment fracture, a minimum height of 6 mm for the crestal transported segment was necessary. Additionally, considering the inferior alveolar nerve (IAN), the goal was to maintain a safe distance of 2 mm of the bone as a safety margin above the nerve. Next, the distraction device (Arabic Engineers for Designs and Medical Instrument, Cairo, Egypt, Manufactured by JEIL Medical Corporation Company: Seoul, Korea. www.jeilmed.co.kr) was fixed with mini and micro-screws to the preplanned position. Bone elongation was initiated after a 5-day latency period at a rate of 0.5 mm/day until the required height had been achieved. We performed a slight overcorrection of 2 to 3 mm because we anticipated that the force of mastication would cause a partial vertical relapse during the retention period. The distractor was left in place for an additional three months to allow for bony consolidation before being removed (14).

Follow-up Phase

The follow-up schedule was 24 hours, 5 days, every day for 2 weeks, 4 weeks, and 3 months after

activation. The clinical follow-up included an assessment of postoperative pain and wound healing. Regarding pain, pain intensity was evaluated. The pain intensity scores were measured at 24 hours, 1 week, and two weeks postoperatively, where the pain intensity score scaled from 0 (No pain) to 10 (Most severe pain) according to the visual analog scale (VAS). The sutured wounds were examined for signs and symptoms of infection including swelling, redness, hotness, pus discharge in addition to observation for any manifestations of wound healing disturbance, as wound dehiscence and hardware exposure at 1, 7 and 14 days postoperatively.

Postoperative CBCT scan was taken immediately postoperative, post-activation, and 3 months post-activation to evaluate the bone density at the distracted area, and the length gained.

Radiographic evaluation

Bone density

The Mean Bone Density was assessed in four different periods: preoperatively, immediate postoperative, post-activation, and 3 months post-activation. The mean value was obtained by assigning 6 different similar cutting lines on the panoramic view in each CBCT scan, and in the corresponding cross-section view, the Region of Interest (ROI) was assigned, and the value was obtained. The mean ROI of the 6 assigned trajectory lines was calculated.

Vertical length

The Mean vertical length was assessed in four different periods: preoperatively, immediate postoperative, post-activation, and 3 months post-activation. The mean value was obtained by assigning 6 different similar cutting lines on the panoramic view in each CBCT scan, and in the corresponding cross-section view, the length was measured from the crest of the ridge to the upper border of the inferior alveolar canal. Statistical analysis of the data

The computer was fed data, which was then analyzed with IBM SPSS software. The Shapiro-Wilk test was used to ensure that the distribution was normal. Range (minimum and maximum), mean, and standard deviation were used to describe quantitative data. The obtained results were judged significant at the 5% level.

The tests used were paired t-test for normally distributed quantitative variables, to compare between two periods, ANOVA with repeated measures, to compare between more than two periods or stages, and Post Hoc Test (adjusted Bonferroni) for pairwise comparisons, Wilcoxon signed ranks test for abnormally distributed quantitative variables, to compare between two periods, Friedman test for abnormally distributed quantitative variables, to compare between more than two periods or stages and Post Hoc Test (Dunn's) for pairwise comparisons.

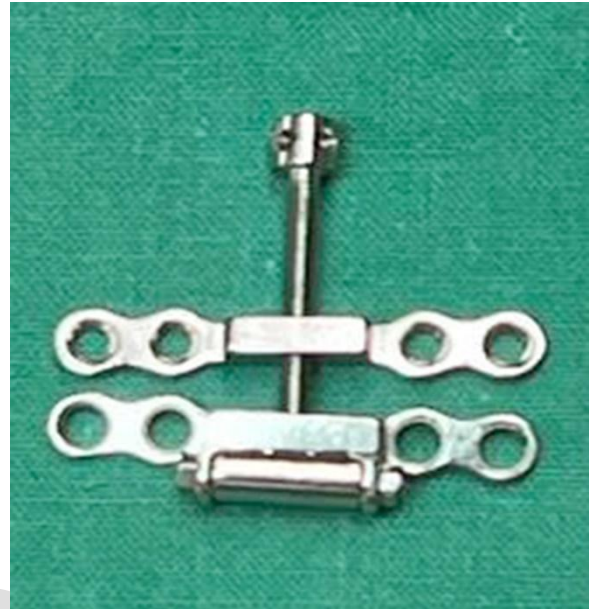

Figure (1): Showing the alveolar distractor

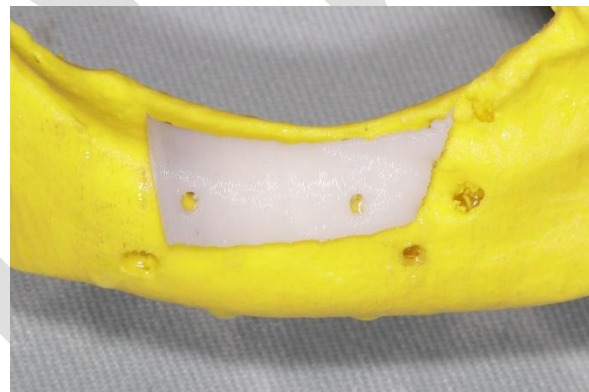


Figure (2): The final surgical guide on the model

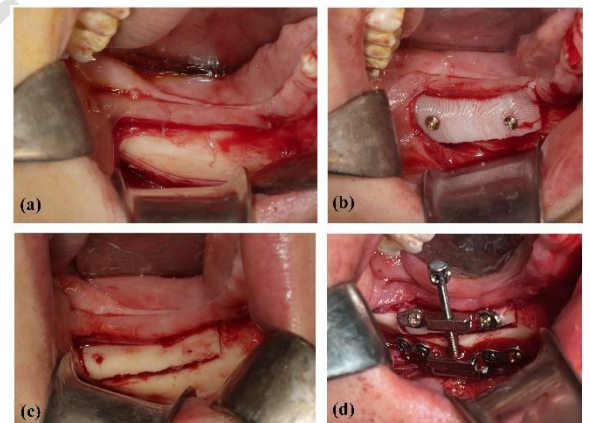


Figure (3): Showing the operation steps.

- (a) Buccal mucoperiosteal flap elevation.
- (b) Fixation of the surgical guide.
- (c) Cutting the transport segment.
- (d) Fixation of the distractor.

RESULTS

Epidemiology and demographic data

The entire sample was 2 males (28.6%) and 5 females (71.4%). The seven locations of atrophic sites were 5 located on the right side (71.4%) and the other 2 located on the left side (28.6%). Patients' age ranged from 35 – 50 years old with a total mean of 41.43 ± 5.56 . Tooth extraction was the etiologic factor in all cases of atrophic posterior alveolar mandible in this study.

Clinical results

Pain intensity was decreased in all cases throughout the follow-up periods. The mean pain score was 4.57 ± 0.79 after 24 hrs., 2.0 ± 0.58 after 1 week, and 0.57 ± 0.53 after two weeks. There was a statistically significant difference in pain intensity scores across the follow-up periods (p -value <0.05) as shown in (Table 1).

All cases proceeded on without any problems, with the surgical site completely healed and all anticipated postoperative inflammatory signs and symptoms subsided. There were no occurrences of infections, wound dehiscence, transported segment fracture, distractor fracture, or other major complications.

Radiographical results

The mean bone density immediate postoperative range was 200.3 ± 46.3 and 89.27 ± 37.51 post-activation. While the bone density was significantly increased in the 3 months post-activation with a mean range of 377.34 ± 18.58 .

The comparison between the preoperative, the immediate postoperative, post-activation, and the 3 months post-activation was statistically significant at $p \leq 0.05$. (Table 2)

The mean vertical alveolar bone length immediate postoperative range was 8.40 ± 0.55 then increased to 15.11 ± 2.42 post-activation. After that, a little decrease in the bone length significantly appeared in the 3 months post-activation with a mean range of 13.54 ± 1.98 .

The comparison between the vertical alveolar bone length preoperative, the immediate postoperative, post-activation, and the 3 months post-activation was statistically significant at $p \leq 0.05$. (Table 3)

Table (1): Comparison between the different studied periods according to pain

Pain	1 st day (n=7)	1 st week (n=7)	2 weeks (n=7)	p
Min. – Max.	4.0 – 6.0	1.0 – 3.0	0.0 – 1.0	0.001 *
Mean ± SD.	4.57 ± 0.79	2.0 ± 0.58	0.57 ± 0.53	
Sig. bet. periods	p ₁ =0.045*, p ₂ <0.001*, p ₃ =0.109			

p: p value for comparing between the different studied periods.

p₁: p value for comparing between 1st and 1 week.
p₂: p value for comparing between 1st and 2 weeks.
p₃: p value for comparing between 1st week and 2 weeks.

*: Statistically significant at $p \leq 0.05$

Table (2): Comparison between the different studied periods according to bone density

Bone density	Preoperative (n=7)	Postoperative (n=7)	Post activation (n=7)	3 months (n=7)	p
Min. – Max.	518.4 – 715.5	135.0 – 256.50	34.0 – 130.30	353.0 – 402.0	<0.001*
Mean \pm SD.	613.19 ± 58.81	200.3 ± 46.3	89.27 ± 37.51	377.34 ± 18.58	
p ₀		<0.001*	<0.001*	<0.001*	
Sig. bet. periods		$p_1=0.002^*$, $p_2=0.002^*$, $p_3<0.001^*$			

p: p value for comparing between the different studied periods.

p₀: p value for comparing between Preoperative and each other periods.

p₁: p value for comparing between Post operative and post activation.

p₂: p value for comparing between Postoperative and 3 months.

p₃: p value for comparing between Post activation and 3 months.

*: Statistically significant at $p \leq 0.05$

Table (3): Comparison between the different studied periods according to bone length

Bone length	Preoperative (n=7)	Postoperative (n=7)	Post-Activation (n=7)	3 months (n=7)	p
Min. – Max.	7.40 – 8.60	7.90 – 9.20	10.50 – 18.70	10.0 – 15.70	<0.001*
Mean \pm SD.	7.90 ± 0.36	8.40 ± 0.55	15.11 ± 2.42	13.54 ± 1.98	
p ₀		0.219	0.001*	0.001*	
Sig. bet. periods		$p_1=0.001^*$, $p_2=0.001^*$, $p_3=0.037^*$			

p: p value for comparing between the different studied periods.

p₀: p value for comparing between Preoperative and each other period.

p₁: p value for comparing between **Postoperative** and **post activation**.

p₂: p value for comparing between **Post operative** and **3 months**.

p₃: p value for comparing between post **Post activation** and **3 months**.

*: Statistically significant at $p \leq 0.05$

DISCUSSION

Implant placement in the atrophic posterior mandible presents a significant challenge. ADO enables the use of longer implants with shorter crowns. Not only does this enhance implant prognosis, but also improves esthetics. Multiple studies have shown that alveolar distraction is effective in preserving the crown-to-implant length ratio (30, 31).

This research was done on 7 patients whose ages ranged from 35 – 50 years old, the seven locations of atrophic sites were 5 located on the right side and 2 located on the left side.

The study found that the surgical site healed completely, and all expected postoperative inflammatory signs and symptoms resolved without any complications such as infections, wound dehiscence, fracture of the transported segment, fracture of the distractor, or other major complications. The success of the study is attributed to the adherence to the guidelines provided by Saulacic et al. Saulacic et al. emphasized the importance of maintaining excellent oral hygiene, particularly around the distraction rod, as well as having a comprehensive knowledge of the technique and appropriate patient selection (32).

The pain intensity decreased in all cases during the follow-up periods, which may be associated with the resolution of inflammation and complete wound healing.

According to Lazar et al., they observed a decreased tendency for bone resorption, a lower infection rate, and the lack of any wound dehiscence. This could be due to the preserved periosteal nutrition of the osteomized alveolar ridge segment (33). However, Altaweel et al. mentioned that wound dehiscence and plate exposure occurred in 5 out of twenty patients in their study (29).

The osteotomy is a critical step in alveolar distraction osteogenesis. Preserving the periosteum's integrity during lingual osteotomy is crucial for maintaining vascularization and preventing necrosis of the transported segment.

The osteotomy must be very precise, and this is where piezoelectric osteotomy comes in handy. Piezoelectric osteotomy selectively cuts bone without affecting nearby soft tissues making it an attractive option for precise osteotomies and decreasing the risk of nerve injuries (22, 34).

According to Rachmiel et al, (14), a minimal height of 6 mm is essential for proper fixation of the distractor and to prevent fracture of the transported segment. This finding is consistent with our study, which reported a mean preoperative vertical length of $8.40 \pm 0.55\text{mm}$.

Three months after activation, the CBCT radiograph showed promising vertical lengthening and gradual radiopacity at the distracted area.

In our study, we observed a notable increase in bone density during the distraction periods which agreed with Altaweel et al who showed improvement in bone density measurements at the termination of the consolidation period of their two groups (29).

When using (ADO), it is necessary to consider the elongation direction and the stability of the crestal transported segment. In addition, a sufficient retention period is needed to ensure that newly formed bone is strong and stable before placing dental implants (13, 32). It is critical to place the flap incision correctly to regenerate a good-quality of bone as a final result. The buccal to crestal incision with the preservation of the lingual and crestal mucosal attachments allows for enough blood supplies to the transported segment which reduces the resorption and prevents damage to nearby structures. In the literature, it is also known that onlay bone grafts or guided bone regeneration are less stable than alveolar distraction osteogenesis concerning resorption and relapse (35).

Chiapasco et al (36) conducted a study comparing guided bone regeneration versus alveolar distraction osteogenesis in the treatment of cases with vertical deficiency and follow-up 3 years after loading implants by their prosthesis. According to the results, alveolar distraction emerges as a more reliable and predictable method for achieving long-term results. The researchers did a comparison between ADO and autogenous onlay bone grafts, their findings revealed that bone resorption was markedly reduced in the alveolar distraction group (37).

In contrast, there is a systematic review done by Yun et al comparing alveolar distraction osteogenesis versus onlay bone grafting, the findings were no statistically significant difference between them regarding the process of bone resorption and bone gain (38).

The comparison between the two techniques of inlay bone graft versus ADO in the posterior mandible was done by Bianchi et al. to measure the vertical bone gain. They discovered that using DO led to significantly greater vertical bone augmentation (10 mm vs 5.8 mm) (39).

In our study, the mean vertical length was 13.54 ± 1.98 which coincides with Rachmiel et al with a mean vertical length of 14.47 in their study (14).

Following vertical alveolar distraction, the percentage between 3 to 20% of bone gained vertically may be relapsed due to mastication force and muscle action (14, 32, 40). Because of this anticipated relapse, we performed a 2 to 3 mm overcorrection in our study.

Kumar et al observed that there was little bone resorption with alveolar distraction osteogenesis after the treatment of anterior mandibular atrophies (17).

Recent research by Altaweel et al (29) also supported our result that there was a significant increase in bone height at the termination of the activation period, which was followed by a significant decrease at the termination of the consolidation period as he mentioned in both groups of his study as stated group I (control group) with mean bone height of 8.3 ± 2.3 mm before distraction, 13.6 ± 1.4 mm after activation and 11.5 ± 1.4 mm at end of consolidation period. While in group II (study group), it was 8.4 ± 1 mm before distraction then became 13.2 ± 1.5 mm after activation and 12.7 ± 1.2 mm at the end of the consolidation period.

Although there have been many previous studies on alveolar distraction osteogenesis, this study is a special trial to improve the accuracy of the operation and reduce complications in every single step by using piezo surgery and designing many guides. The 1st guide is used to delineate the osteotomies of the transported segment preoperatively. The 2nd one assessed the preoperative position of the inferior alveolar nerve to minimize the risk of nerve injury during bone cutting intraoperatively. Finally, the use of a final surgical guide inside the operation to guide the osteotomies and to allow for the accurate position of the preadapted distractor on the planned holes strengthens our study and reduces the possibility of complications such as distractor fracture or transport segment fracture.

CONCLUSIONS

Alveolar Distraction Osteogenesis is a useful method that provides significant vertical ridge augmentation while simultaneously expanding soft tissue and producing long-term stable results. It is useful in the treatment of bony atrophies and promotes sufficient bone formation with good quality and density which allows for implant placement easily. This technique also shows a decrease in the pain intensity and promising wound healing results through the study periods. The application of different guides to guide the osteotomies, determine the position of the inferior alveolar canal, and accurately position the distractor on the planned holes greatly decreases intraoperative time, decreases risks for IAN injury, accurately positions the transported segment, and prevents distractor fracture.

Conflict of interest:

The authors declare that they have no conflicts of interest.

REFERENCES

1. Jung RE, Pjetursson BE, Glauser R, Zembic A, Zwahlen M, Lang NP. A systematic review of the 5-year survival and complication rates of implant-supported single crowns. *Clin Oral Implants Res.* 2008;19:119-30.
2. Bell RB, Blakey GH, White RP, Hillebrand DG, Molina A. Staged reconstruction of the severely atrophic mandible with autogenous bone graft and endosteal implants. *J Oral Maxillofac Surg.* 2002;60:1135-41.
3. Nguyen TTH, Eo MY, Kuk TS, Myoung H, Kim SM. Rehabilitation of atrophic jaw using iliac onlay bone graft combined with dental implants. *Int J Implant Dent.* 2019;5:11.
4. Drăgan E, Nemțoi A. Review of the Long-Term Outcomes of Guided Bone Regeneration and Autologous Bone Block Augmentation for Vertical Dental Restoration of Dental Implants. *Med Sci Monit.* 2022;28:e937433.
5. Amaral Valladão CA, Freitas Monteiro M, Joly JC. Guided bone regeneration in staged vertical and horizontal bone augmentation using platelet-rich fibrin associated with bone grafts: a retrospective clinical study. *Int J Implant Dent.* 2020;6:72.
6. Jensen OT. Alveolar Segmental "Sandwich" Osteotomies for Posterior Edentulous Mandibular Sites for Dental Implants. *J Oral Maxillofac Surg.* 2006;64:471-5.
7. Sheikh Z, Sima C, Glogauer M. Bone Replacement Materials and Techniques Used for Achieving Vertical Alveolar Bone Augmentation: Materials (Basel). 2015 May 27;8(6):2953-93. doi: 10.3390/ma8062953. eCollection 2015 Jun.
8. Adolphs N, Sproll C, Raguse J, Nelson K, Heberer S, Klein M, et al. Stable vertical distraction osteogenesis of highly atrophic mandibles—a salvage pathway for mandibular reconstruction prior to oral rehabilitation with dental implants. *Int J Oral Maxillofac Implants.* 2009;38:461.
9. Lorean A, Kablan F, Mazor Z, Mijiritsky E, Russe P, Barbu H, et al. Inferior alveolar nerve transposition and reposition for dental implant placement in edentulous or partially edentulous mandibles: a multicenter retrospective study. *Int J Oral Maxillofac Surg.* 2013;42:656-9.
10. Hwang SJ, Jung JG, Jung JU, Kyung SH. Vertical alveolar bone distraction at molar region using lag screw principle. *J Oral Maxillofac Surg.* 2004;62:787-94.
11. Atef M, Mounir M. Computer-guided inferior alveolar nerve lateralization with simultaneous implant placement: a preliminary report. *J Oral Implantol.* 2018;44:192-7.
12. Karlis V, Bae RD, Glickman RS. Mandibular fracture as a complication of inferior alveolar nerve transposition and placement of endosseous implants: a case report. *Implant Dent.* 2003;12:211-6.
13. Aizenbud D, Hazan-Molina H, Cohen M, Rachmiel A. Combined orthodontic temporary anchorage devices and surgical management of the alveolar ridge augmentation

- using distraction osteogenesis. *J Oral Maxillofac Surg.* 2012;70:1815-26.
14. Rachmiel A, Shilo D, Aizenbud D, Emodi O. Vertical alveolar distraction osteogenesis of the atrophic posterior mandible before dental implant insertion. *J Oral Maxillofac Surg.* 2017;75:1164-75.
 15. Ilizarov GA. The tension-stress effect on the genesis and growth of tissues: Part I. The influence of stability of fixation and soft-tissue preservation. *Clin Orthop Relat Res.* 1989;238:249-81.
 16. van Strijen PJ, Breuning KH, Becking AG, Perdijk FB, Tuinzing DB. Complications in bilateral mandibular distraction osteogenesis using internal devices. *Oral Surg Oral Med Oral Pathol Oral Radiol Endod.* 2003;96:392-7.
 17. Kumar KA, Masrom AK, Patil K, Kunusoth R, Begum F, Venkatesh V. Evaluation of Vertical Bone Gain Following Alveolar Distraction Osteogenesis in the Anterior Edentulous Mandible: A Clinical Study. *J Maxillofac Oral Surg.* 2014;13:539-45.
 18. Esposito M, Grusovin MG, Felice P, Karatzopoulos G, Worthington HV, Coulthard P. The efficacy of horizontal and vertical bone augmentation procedures for dental implants - a Cochrane systematic review. *Eur J Oral Implantol.* 2009;2:167-84.
 19. Louvrier A, Marty P, Barrabé A, Euvrard E, Chatelain B, Weber E, et al. How useful is 3D printing in maxillofacial surgery? *J Stomatol Oral Maxillofac Surg.* 2017;118:206-12.
 20. Jacobs CA, Lin AY. A New Classification of Three-Dimensional Printing Technologies: Systematic Review of Three-Dimensional Printing for Patient-Specific Craniomaxillofacial Surgery. *Plast Reconstr Surg.* 2017;139:1211-20.
 21. Agarwal E, Masamatti SS, Kumar A. Escalating role of piezosurgery in dental therapeutics. *J Clin Diagn Res.* 2014;8:ZE08.
 22. Deepa D, Jain G, Bansal T. Piezosurgery in dentistry. *J Oral Res Rev.* 2016;8:27-31.
 23. Schulz KF, Altman DG, Moher D. CONSORT 2010 statement: Updated guidelines for reporting parallel group randomized trials. *Ann Intern Med.* 2011;154:291-2.
 24. Rosner B. Fundamentals of biostatistics. Boston: Cengage Learning, Inc; 2010.
 25. Buchner A, Erdfelder E, Faul F, Lang A. G* Power: statistical power analyses for Mac and Windows. Heinrich-Heine-Universität Düsseldorf. 2001.
 26. Greene JC, Vermillion JR. THE SIMPLIFIED ORAL HYGIENE INDEX. *J Am Dent Assoc.* 1964;68:7-13.
 27. Török G, Gombocz P, Bognár E, Nagy P, Dinya E, Kispélyi B, et al. Effects of disinfection and sterilization on the dimensional changes and mechanical properties of 3D printed surgical guides for implant therapy - pilot study. *BMC Oral Health.* 2020;20:19.
 28. Robiony M, Toro C, Stucki-McCormick SU, Zerman N, Costa F, Politi M. The "FAD"(Floating Alveolar Device): A bidirectional distraction system for distraction osteogenesis of the alveolar process. *J Oral Maxillofac Surg.* 2004;62:136-42.
 29. Altaweel AA, Baiomy A, Shoshan HS, Abbas H, Abdel-Hafiz AA, Gaber AE, et al. Evaluation of osteogenic potential of *Cissus quadrangularis* on mandibular alveolar ridge distraction. *BMC Oral Health.* 2021;21:491.
 30. Uckan S, Haydar SG, Dolanmaz D. Alveolar distraction: analysis of 10 cases. *Oral Surg Oral Med Oral Pathol Oral Radiol Endod.* 2002;94:561-5.
 31. Garcia-Garcia A, Somoza-Martin M, Gandara-Vila P, Saulacic N, Gandara-Rey J. Alveolar distraction before insertion of dental implants in the posterior mandible. *Br J Oral Maxillofac Surg.* 2003;41:376-9.
 32. Saulacic N, Zix J, Iizuka T. Complication rates and associated factors in alveolar distraction osteogenesis: a comprehensive review. *Int J Oral Maxillofac Surg.* 2009;38:210-7.
 33. Millesi-Schobel GA, Millesi W, Glaser C, Watzinger F, Klug C, Ewers R. The L-shaped osteotomy for vertical callus distraction in the molar region of the mandible: a technical note. *J Craniomaxillofac Surg.* 2000;28:176-80.
 34. González-García A, Diniz-Freitas M, Somoza-Martín M, García-García A. Piezoelectric and conventional osteotomy in alveolar distraction osteogenesis in a series of 17 patients. *Int J Oral Maxillofac Implants.* 2008;23.
 35. Keestra JAJ, Barry O, Jong LD, Wahl G. Long-term effects of vertical bone augmentation: a systematic review. *J Appl Oral Sci.* 2016;24:3-17.
 36. Chiapasco M, Romeo E, Casentini P, Rimondini L. Alveolar distraction osteogenesis vs. vertical guided bone regeneration for the correction of vertically deficient edentulous ridges: a 1–3-year prospective study on humans. *Clin Oral Implants Res.* 2004;15:82-95.
 37. Chiapasco M, Zaniboni M, Rimondini L. Autogenous onlay bone grafts vs. alveolar distraction osteogenesis for the correction of vertically deficient edentulous ridges: a 2–4-year prospective study on humans. *Clin Oral Implants Res.* 2007;18:432-40.
 38. Yun KI, Choi H, Wright RF, Ahn HS, Chang BM, Kim HJ. Efficacy of Alveolar Vertical Distraction Osteogenesis and Autogenous Bone Grafting for Dental Implants: Systematic Review and Meta-Analysis. *Int J Oral Maxillofac Implants.* 2016;31:26-36.
 39. Bianchi A, Felice P, Lizio G, Marchetti C. Alveolar distraction osteogenesis versus inlay bone grafting in posterior mandibular atrophy: a prospective study. *Oral Surg Oral Med Oral Pathol Oral Radiol Endod.* 2008;105:282-92.
 40. Kim J-W, Cho M-H, Kim S-J, Kim M-R. Alveolar distraction osteogenesis versus autogenous onlay bone graft for vertical augmentation of severely atrophied alveolar ridges after 12 years of long-term follow-up. *Oral Surg Oral Med Oral Pathol Oral Radiol.* 2013;116:540-9.